Journal of Feline Medicine and Surgery (2022) **24**, 905–933

SPECIAL ARTICLE

2022 AAFP/EveryCat Feline Infectious Peritonitis Diagnosis Guidelines



Clinical importance: Feline infectious peritonitis (FIP) is one of the most important infectious diseases and causes of death in cats; young cats less than 2 years of age are especially vulnerable. FIP is caused by a feline coronavirus (FCoV). It has been estimated that around 0.3% to 1.4% of feline deaths at veterinary institutions are caused by FIP.

Scope: This document has been developed by a Task Force of experts in feline clinical medicine as the 2022 AAFP/EveryCat Feline Infectious Peritonitis Diagnosis Guidelines to provide veterinarians with essential information to aid their ability to recognize cats presenting with FIP.

Testing and interpretation: Nearly every small animal veterinary practitioner will see cases. FIP can be challenging to diagnose owing to the lack of pathognomonic clinical signs or laboratory changes, especially when no effusion is present. A good understanding of each diagnostic test's sensitivity, specificity, predictive value, likelihood ratio and diagnostic accuracy is important when building a case for FIP. Before proceeding with any diagnostic test or commercial laboratory profile, the clinician should be able to answer the questions of 'why this test?' and 'what do the results mean?' Ultimately, the approach to diagnosing FIP must be tailored to the specific presentation of the individual cat.

Relevance: Given that the disease is fatal when untreated, the ability to obtain a correct diagnosis is critical. The clinician must consider the individual patient's history, signalment and comprehensive physical examination findings when selecting diagnostic tests and sample types in order to build the index of suspicion 'brick by brick'. Research has demonstrated efficacy of new antivirals in FIP treatment, but these products are not legally available in many countries at this time. The Task Force encourages veterinarians to review the literature and stay informed on clinical trials and new drug approvals.

Keywords: Feline infectious peritonitis; FIP; FCoV; feline coronavirus; diagnosis; effusion; antibody; infection; fluid; blood test; analysis; cytology; Rivalta; AFAST; imaging; screening; laboratory sample; lesion; virus; RNA; RNA virus; polymerase chain reaction; PCR; PCR testing

Vicki Thayer
DVM, DABVP (Feline)*
Co-Chair
Purrfect Practice PC,
Lebanon, OR, USA

Susan Gogolski
DVM, DABVP
(Canine/Feline)*
Co-Chair
Colorado State University,
Fort Collins, CO, USA

Sandra Felten
DVM, DECVIM-CA
Ludwig-Maximilians-
University, Munich, Germany

Katrin Hartmann
DVM, DECVIM-CA
Ludwig-Maximilians-
University, Munich, Germany

Melissa Kennedy
DVM, PhD, DACVIM
University of Tennessee,
Knoxville, TN, USA

Glenn A Olah
DVM, PhD, DABVP (Feline)
Albuquerque Cat Clinic,
Albuquerque, NM, USA

*Corresponding authors:
thayv@aol.com
dvm_smgogo@yahoo.com

Introduction

Feline infectious peritonitis (FIP) was first described as a specific disease entity in 1963 by Dr Jean Holzworth and colleagues at the Angell Memorial Animal Hospital in Boston, USA.[1] FIP commonly occurs in cats originating from catteries, shelters and foster/rescue groups, as the prevalence of feline coronavirus (FCoV) infection is high in cats living in crowded conditions.[2] Cats that have recently undergone a stressful event are also more likely to develop FIP. In addition, young cats (less than 2 years of age) are especially vulnerable.[3]

FIP is one of the most important infectious diseases of cats, and nearly every small animal veterinary practitioner will see cases, especially those working closely with shelters, rescue groups and/or breeders. More complex cases are often seen by specialists and at university hospitals. It has been estimated that around 0.3% to 1.4% of feline deaths at veterinary institutions are caused by FIP.[3–5] FIP can be challenging to diagnose owing to the lack of pathognomonic clinical signs or laboratory changes, especially when no effusion is present. However, given that the disease is fatal when untreated, the ability to obtain a correct diagnosis is critical.

The 2022 AAFP/EveryCat Feline Infectious Peritonitis Diagnosis Guidelines have been developed by a Task Force of experts in feline clinical medicine to provide veterinarians with essential information to aid their ability to recognize cats presenting with FIP.

The International Society of Feline Medicine (ISFM) is pleased to endorse these practice guidelines from the AAFP and EveryCat Health Foundation.

DOI: 10.1177/1098612X221118761
© 2022 by American Association of Feline Practitioners, EveryCat Health Foundation and International Society of Feline Medicine

FIP was once considered a terminal diagnosis, but research has demonstrated efficacy of new antivirals in FIP treatment.



CONTENTS

	page
Introduction	905
Characteristics of feline coronaviruses	906
Epidemiology of feline coronavirus infection	907
Pathogenesis of FIP	908
Diagnosis of FIP	908
Signalment and history	909
Physical examination findings	910
Differential diagnoses	914
Diagnostic testing	914
– Effusion analysis	915
– Diagnostic imaging	917
– Histopathology	922
– Detection of viral nucleic acid	922
– Detection of viral antigen	924
– Detection of anti-FCoV antibodies	924
Summary of diagnostic testing for FIP	927
Key points	927
Supplementary material	928
Glossary	928
References	929

Helpful tips are provided throughout the document, together with multiple clinical images and tables; algorithms and other supplemental resources appear online (see list of supplementary material on page 928).

FIP was once considered a terminal diagnosis. Research has demonstrated efficacy of new antivirals in FIP treatment, but these products are not legally available in many countries at this time. Veterinarians are encouraged to review the literature and stay informed on clinical trials and new drug approvals.

Characteristics of feline coronaviruses

FIP is caused by an FCoV. FCoVs are enveloped, positive-stranded ribonucleic acid (RNA) viruses characterized by club-like spikes that project from their surface and have unusually large viral RNA genomes (see supplemental figure 1).[6] They belong to the order Nidovirales, family Coronaviridae and subfamily Coronavirinae.

Coronavirinae are subdivided into four genera based on genetic and antigenic characteristics: alpha (α)-, beta (β)-, gamma (γ)- and delta (δ)-CoV. FCoV belongs to the α-coronavirus genus and is taxonomically distant from SARS-CoV-2, a member of the β-coronavirus genus and the causative agent of coronavirus disease 2019 (COVID-19).[7,8] FCoV occurs in

ABBREVIATIONS

- AFAST (abdominal focused assessment with sonography for trauma, triage and tracking)
- AGP (alpha-1-acid glycoprotein)
- A:G ratio (albumin to globulin ratio)
- ALP (alkaline phosphatase)
- ALT (alanine aminotransferase)
- CC (Cysto-Colic)
- CCoV (canine coronavirus)
- cDNA (complementary DNA)
- CNS (central nervous system)
- COVID-19 (coronavirus disease 2019)
- CSF (cerebrospinal fluid)
- CT (computed tomography)
- DH (Diaphragmatico-Hepatic)
- DNA (deoxyribonucleic acid)
- EDTA (ethylenediaminetetraacetic acid)
- ELISA (enzyme-linked immunosorbent assay)
- FCoV (feline coronavirus)
- FCoV mRNA (feline coronavirus messenger-ribonucleic acid)
- FECV (feline enteric coronavirus)
- FeLV (feline leukemia virus)
- FIP (feline infectious peritonitis)
- FIPV (feline infectious peritonitis virus)
- FIV (feline immunodeficiency virus)
- FNA (fine-needle aspirate)
- HRU (Hepato-Renal Umbilical)
- ICC (immunocytochemistry)
- ICS (intercostal space)
- IF (immunofluorescence)
- IFA (immunofluorescence antibody)
- Ig (immunoglobulin)
- IHC (immunohistochemistry)
- LR (likelihood ratio)
- MHC (major histocompatibility complex)
- MLN (mesenteric lymph node)
- MRI (magnetic resonance imaging)
- NPV (negative predictive value)
- PBMC (peripheral blood mononuclear cell)
- PCE (pericardial effusion)
- PCR (polymerase chain reaction)
- PCS (pericardial site)
- PE (pleural effusion)
- POCUS (point-of-care ultrasound)
- PPV (positive predictive value)
- Real-time RT-PCR (real-time reverse transcriptase-polymerase chain reaction)
- RNA (ribonucleic acid)
- RT-nPCR (reverse transcriptase-nested polymerase chain reaction)
- RT-qPCR (reverse transcriptase-quantitative polymerase chain reaction)
- *7b*-RT-qPCR (*7b* gene reverse transcriptase-quantitative polymerase chain reaction)
- S protein/*S* gene (spike protein/gene)
- SARS-CoV-2 (severe acute respiratory syndrome coronavirus 2)
- SR (Spleno-Renal)
- TCB (Tru-cut biopsy)
- TFAST (thoracic focused assessment with sonography for trauma, triage and tracking)

two serotypes (types I and II), which encompass numerous strains.[9,10] FCoV serotypes differ in their neutralizing antibody reactions and have distinct spike (S) protein sequences.[11–13] Type II is less prevalent in most cat populations compared with type I,[14,15] and likely originated from recombination between FCoV type I and canine coronaviruses (see supplemental figure 2).[12,16–18] While serotype II uses the feline aminopeptidase-N receptor present on the intestinal villi[19,20] for cell entry, the cellular receptor for serotype I is still unknown.[20,21] Serotype II FCoV is easily grown in cell culture, while serotype I FCoV is difficult to culture.

FCoV occurs as two different bio-/pathotypes,[9,22,23] which differ in virulence: a non-mutated harmless biotype (also called feline enteric coronavirus [FECV]), which is very common in multi-cat populations, and a mutated virulent biotype (also called feline infectious peritonitis virus [FIPV]), which causes FIP. Infection always involves the non-mutated biotype, but in a small proportion of cats infected with FCoV (7–14% in multi-cat environments), a spontaneous mutation will occur in individual cats leading to a change in cell tropism from enterocytes to an affinity for monocytes/macrophages.[10,24–26] This biotype switch is a key event in the pathogenesis of FIP. Non-mutated and mutated FCoV biotypes from the same environment are >99% related, yet vary uniquely in their virulence.[24]

A key event in the pathogenesis of FIP is a switch from the non-mutated to the more virulent mutated FCoV biotype.

Epidemiology of feline coronavirus infection

FCoV is found globally and is ubiquitous in most cat populations.[27,28] It is highly contagious and spreads efficiently via fecal–oral transmission, allowing for high prevalence in multi-cat environments, such as breeding catteries,[2] shelter/rescue facilities and animal hoarding situations.[28] In particular, FCoV infection is common when living conditions are crowded, and litter boxes and feeding bowls are shared (see supplemental figure 3).[29–34] In one study, real-time reverse transcriptase-quantitative polymerase chain reaction (RT-qPCR) determined the prevalence of FCoV shedding to be 77% in 179 cats from 37 German catteries.[2] None of the 37 tested catteries was free of FCoV. A few other studies on FCoV shedding in single catteries or shelters have revealed prevalences ranging from 74% to 100%.[30,35] In an investigation of cats before and after being placed in shelters in California, USA, the overall prevalence of FCoV shedding upon admission was 33% in all cats, and 90% in kittens and young cats under 56 weeks of age;[36] the prevalence increased significantly, particularly among adult cats, when they were housed together in a shelter environment.[36]

Initially, when a cat is infected with FCoV, the virus replicates within the mature apical columnar epithelial cells of the small intestinal villi from the distal duodenum to the cecum.[37] In some cats, persistent infection of colonic columnar epithelial cells occurs (see supplemental figure 4a).[30,38,39] Cats start to shed virus within the first 7 days, usually as early as 2–3 days post-infection, and generally continue to shed virus for several weeks, with some cats shedding virus for up to 18 months or even lifelong.[9,32,40] The amount of virus shed is especially high during the early phase of infection;[9,38] in most cats the viral load then gradually decreases and shedding can stop entirely, but all remain susceptible to reinfection and will then shed again.[9,30,32,36,41,42] Very few cats seem to be resistant and never shed the virus.[9,17,30,32,36,40–42]

Kittens in multi-cat environments where FCoV is endemic usually become infected within the first weeks of life;[9,40] indeed, FCoV infection has been demonstrated in kittens as young as 2–4 weeks old.[43] These early infections have raised questions about the effectiveness of protection by maternal antibodies; nevertheless, early weaning of kittens is not recommended.[28,44]

Kittens less than 1 year of age are 2.5 times more likely to shed FCoV than adult cats,[2] and kittens typically shed significantly higher viral loads than older cats.[2] High amounts of viral shedding in kittens under 6 months of age can be explained by the immaturity of their immune system, allowing the virus to replicate efficiently.[9,36] The higher viral loads of young cats imply higher levels of viral replication and, thus, increased risk of mutation of FCoV to the more virulent biotype.[9]

OUTCOMES OF PRIMARY FCoV INFECTION

Three scenarios have been documented associated with primary FCoV infection:[40,45]

- Cats are fairly resistant to infection, with quick cessation of shedding, or never shed the virus at all (about 5%);
- Cats develop temporary low-level shedding for 2–3 months or longer, and only shed intermittently (about 70–80%);
- Cats develop long-term persistent shedding of high viral loads (about 10–15%).

Due to the high mutation rate of FCoV, infected cats shed a cluster of genetically related but distinct viral populations, known as quasispecies or mutant cloud. Infected cats can continuously be reinfected with the same or different FCoV strains.[42,46] Several studies in catteries and other multi-cat environments have demonstrated at least one cat shedding

FCoV at any one time.[2,9,10,28,43,45] In the aforementioned study of cats before and after being placed in shelters in California, FCoV shedding increased 10- to 1 million-fold in some cats after only a week in the shelter.[36]

Owing to the universal presence of FCoV in multi-cat environments, a priority is to prevent FCoV infection – and thus the potential for development of FIP – in vulnerable kittens and cats, where possible, by identifying persistent FCoV shedder cats. To detect FCoV shedders in these situations, each cat should undergo a series of at least three fecal RT-qPCR tests for FCoV at intervals of 1 week to 1 month.[2,28,31,41,45,47,48]

While most cats infected with less-virulent FCoV are asymptomatic and do not require treatment, some can develop gastrointestinal signs (eg, mild vomiting and/or diarrhea).[46,49] If present, these signs are typically self-limiting and of short duration.[9,37,49] However, in a small number of cats, diarrhea can last for weeks to many months.[9,49,50] One study looking at feline enteric pathogens in 100 shelter cats found that FCoV was the only one out of 12 enteric pathogens identified that was significantly more prevalent in cats with diarrhea than in normal cats (58% and 36%, respectively).[51]

Table 1 Risk factors influencing the development of FIP

Risk factor	Examples/comments
Origin	❖ From environment with high FCoV load
Background	❖ FIP diagnosed in the same litter/family lineage[9] ❖ Immunosuppressive therapy[9] ❖ Adoption or acquisition from a cattery, shelter, rescue or rehoming center[62,63] ❖ Recent stressful event:[17,26,54,55,62,64,65] – Surgery (spay, neuter or other) – Vaccination – Gastrointestinal disease – Upper respiratory tract disease – Travel, boarding, attending cat shows – New household member (eg, new baby or pet), moving house
Signalment	❖ Age at exposure to FCoV (less-virulent biotype): <2 years old[66–69] ❖ Sex: intact (male) cats[3,4,5,70,71] ❖ Breed: certain purebred cats (eg, Bengals, Birmans;[3,68] see supplemental file 7)
Health status	❖ Coinfection (eg, FIV, FeLV) or concurrent disease[9,23,72] ❖ Immunosuppression[9]
Housing conditions	❖ Multi-cat household[45,48] ❖ Frequent introductions and reintroductions to new cats[73–75] ❖ Variable lengths of stay in multi-cat environments[76] ❖ Mingling of different age groups[77] ❖ Overcrowding (>5 cats)[63]

Pathogenesis of FIP

Coronavirus genomes possess a high level of genetic variation owing to the high error rate of RNA polymerase and are, thus, prone to genetic mutations. Mutations in an individual cat leading to a switch in cellular tropism (gastrointestinal epithelium to monocytes/macrophages) and infection of monocytes/macrophages are crucial for systemic spread of FCoV (see supplemental figure 4b).[26,52,53] Monocyte/macrophage entry alone is not sufficient for the development of FIP; likely, mutations leading to persistence and efficient replication within and activation of monocytes/macrophages are required (see 'prerequisites' box).[54,55] FCoV strains from different cats with FIP in the same household show mostly unique genetic characteristics, demonstrating that these viruses develop independently in individual cats.[56–58]

Given that FIP is fatal when untreated, the ability to obtain a correct diagnosis is critical.

To date, specific viral mutations leading to the biotype switch remain undetermined. Two single nucleotide polymorphisms in genes encoding the fusion peptide of the S protein, leading to amino acid changes (M1058L and S1060A), were initially shown to be linked to the conversion of the biotype;[25,59] however, they were later suggested to only indicate systemic spread of FCoV irrespective of the development of FIP (ie, identified in healthy cats as well; see supplemental file 5a).[60,61]

PREREQUISITES FOR DEVELOPMENT OF FIP IN FCoV-INFECTED CATS

- Internal mutations of FCoV in an individual cat lead to a switch in cell tropism of FCoV from gastrointestinal epithelial cells to monocytes/macrophages;
- A virulent FIP-associated FCoV acquires the ability to replicate efficiently in monocytes/macrophages, thus allowing rapid systemic spread throughout the body;
- Activation of virulent FIP-associated FCoV-infected monocytes/macrophages leads to pronounced cytokine production and immune system activation.

For more information on pathogenesis, see supplemental files/figures 4c, 4d, 5a, 5b and 6.

Diagnosis of FIP

Diagnosing FIP can be straightforward if a cat with typical signalment (Table 1) presents with effusion, as tests using effusion generally have much higher positive predictive values (PPVs) than those using blood.[78–80] However, if no effusion is present, diagnosis can become quite challenging due to the variety and non-specificity of possible clinical signs.[28,81] FIP can present with systemic signs or signs specifically related to the organs involved, and with or without fever. One study documented fever in only 56% of cats with FIP, and fever was even less common in cats without effusion.[3] Some cats with FIP lack the serum biochemistry abnormalities

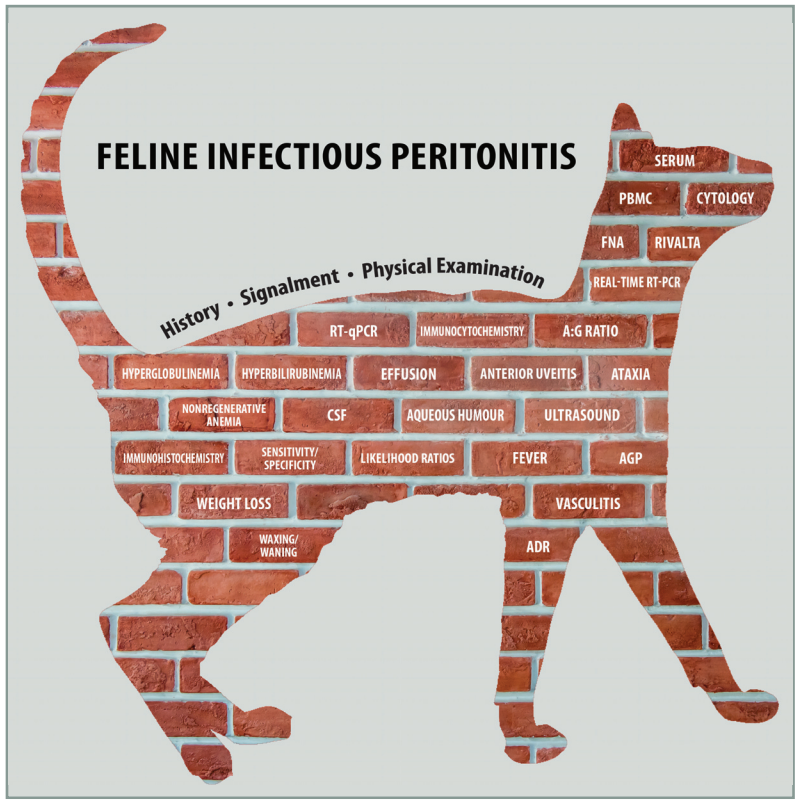

Figure 1 **Diagnostic work-up for FIP. The veterinarian must consider the patient's history, signalment and physical examination findings, and then select diagnostic tests and sample types based on these, in order to build the index of suspicion 'brick by brick'. ADR = 'ain't doing right'. For explanation of other abbreviations, see box on page 906. This figure is available to download from the supplementary material (supplemental figure 8).** *Graphic designed by Vicki Thayer and Susan Gogolski, based on Melissa Kennedy's diagnostic brick wall*

(hyperproteinemia, hyperglobulinemia, hypoalbuminemia, hyperbilirubinemia) that are considered 'typical' for FIP.[78] FIP might not even be on the list of differential diagnoses in cases that do not fit the classic picture (eg, older cat from a single-cat household). Subtle indicators of FIP might also be missed when concurrent disease is present.

The ability to definitively diagnose or have a high index of suspicion ante-mortem that a cat has FIP has been the focus of multiple studies.[28,50,78,80,82–86] To arrive at a diagnosis of FIP, the veterinarian must consider the individual patient's history, signalment and physical examination findings, and select diagnostic tests and sample types accordingly, in order to increase the index of suspicion 'brick by brick' (Figure 1).

When pursuing a diagnosis of FIP, the same or different test modalities can be performed on a variety of sample types, including blood (whole blood, serum, plasma, peripheral blood mononuclear cells [PBMCs]), effusions (thoracic, abdominal, pericardial), tissues, cerebrospinal fluid (CSF), aqueous humour, and/or tissue fine-needle aspirates (FNAs) and biopsies.

Signalment and history

The pathogenenesis of FIP is complex, and susceptibility to FIP in an individual cat involves the interplay between virus virulence factors, host factors such as genetic characteristics, age of the cat at the time of FCoV exposure, concurrent diseases and/or other stressors at a time when a young cat is fighting an FCoV infection.[86–88] Host factors can affect the cat's immune system status, including major histocompatibility complex (MHC) diversity, cytokine production and lymphocyte apoptosis. For example, aspects of MHC II can influence the quality of the immune response.[73,89] Additionally, a link between cytokine- and receptor-associated single nucleotide polymorphisms and increased susceptibility to FIP has been suggested.[62]

A number of risk factors for the development of FIP, related to a cat's signalment and history, have been identified (as listed in Table 1 and outlined below).

✣ **Group housing** In multi-cat environments, up to 12% of FCoV-infected cats will develop FIP,[90,91] and originating from a multi-cat environment clearly is an important risk factor. However, in one study,[3] almost two-thirds of cats diagnosed with FIP were living in single- or two-cat households at the time of diagnosis (a possible explanation being previous exposure to, and prolonged carriage of, FCoV before joining the new household and developing FIP).

✣ **Age** FIP disproportionately affects cats under 2 years of age.[3–5,66–69] Studies in Australia[66] and North Carolina, USA,[4] reported that 55% and 67%, respectively, of cats with FIP were less than 2 years old.

✣ **Sex and neuter status** Some studies have found a predisposition for FIP in male cats.[3,5,14,66,68] In addition, several studies have noted an increased risk for intact cats, males in particular.[4,5,92]

✣ **Breed** Purebred cats are over-represented among cats with FIP, and an inherited susceptibility to the disease has been discussed in pedigree cats.[93] In the North Carolina study,[4] FIP was present in nearly 1.3% of the pedigree cats compared with 0.35% of the mixed-breed cats; 71% of the cats in the Australian study population with FIP were purebred.[66] FIP appears to affect certain family lineages of

Susceptibility to FIP in a cat involves the interplay between virus virulence factors, host factors (eg, genetic characteristics, age), concurrent diseases and/or other stressors at the time of FCoV infection.

cats,[73] and certain breeds appear to be more/less predisposed or over-/under-represented, although the findings differ across studies (see supplemental file 7).[3,68]

❖ **Stress** Stress has also been suggested to increase the risk of developing FIP.[23] In one study,[3] specific previous stressful events were documented in 56.7% of cats diagnosed with FIP. If FIP is on the differential diagnosis list, assessing risk factors through a detailed case history questionnaire, including recent stressors, is a particularly important first step in the diagnostic work-up. A health-related history questionnaire to assist in this process is provided as supplemental file 9.

❖ **Retroviruses** Retroviral infections can be a risk factor for FIP. An association between feline immunodeficiency virus (FIV) infection and an increased risk of FIP was shown in one study.[22] Before the advent of feline leukemia virus (FeLV) vaccination in the 1970s/1980s, 30–50% of cats with FIP had concurrent FeLV infection.[72,86]

Physical examination findings

Cats with FIP commonly have non-specific clinical signs such as anorexia, lethargy, a waxing/waning fever (often non-responsive to antibiotics), lymphadenopathy and weight loss or, for kittens, failure to gain weight (Table 2).[3,86,88,94] These non-specific clinical signs can occur irrespective of the presence of effusion, and may either be reported by owners or, particularly in the early stages of the disease, noted during examination.[3,88,94]

Table 2 Signs associated with FIP

System	Signs
Non-specific	Lethargy, anorexia, weight loss (or failure to gain weight/stunted growth), unthriftiness, fever (waxing/waning; usually <104°F/40°C), jaundice, lymphadenopathy, pale mucous membranes
Abdominal	Distension, fluid wave (ascites), abdominal masses (eg, solitary mural intestinal lesions of colon or ileocecolic junction with regional lymphadenopathy), diarrhea, lymph node enlargement (necrogranulomatous lymphadenitis)
Respiratory	Dyspnea, tachypnea
Cardiac	Cardiac tamponade, heart failure (pericardial effusion)
Reproductive	Scrotal enlargement (effusion), priapism
Neurological	Seizures, abnormal behavior/mentation (dementia, aggression, rage, hiding/withdrawal), central vestibular signs (nystagmus, head tilt, circling, obtunded appearance, postural reaction deficits), anisocoria, ataxia, tetra- or paraparesis, incoordination, hyperesthesia, seizures, palsy (brachial, trigeminal, facial or sciatic nerves), cortical blindness[95]
Ocular	Anterior ± posterior uveitis or chorioretinitis, blindness, hyphema, perivascular cuffing (retinal vasculitis) and fluid accumulation (retinal detachment), hypopyon, fibrinous exudate, keratic precipitates, dyscoria, anisocoria, change in iris color
Dermatological	Toxic epidermal necrolysis, intradermal papules, signs of vasculitis/phlebitis, skin fragility syndrome

Repeated ultrasound examinations should be performed to look for small pockets of abdominal or thoracic effusion that can be sampled for cytological analysis.

Differentiation between 'wet' and 'dry' FIP is not useful since these are not two different disease entities. Although a distinction between 'effusive' (non-parenchymatous) and 'non-effusive' (parenchymatous) forms of FIP (terms that have been used in earlier times) is important for diagnostic purposes, cats initially presenting with non-effusive FIP will commonly develop effusions at a later stage.[28,46,48] Furthermore, pyogranulomatous lesions are found at necropsy in cats presenting with effusive FIP.[28] Since FIP is easier to diagnose when effusion is present, repeated ultrasound examinations should be performed to look for small pockets of abdominal or thoracic effusion that can be sampled for cytological analysis (see later).

Given that the clinical presentation of FIP is so highly variable (see Figures 2–13 in 'the many faces of FIP' box on pages 911–912), a comprehensive physical examination is essential (Figure 14). Mild fever in an otherwise healthy kitten can be the first clue of illness. Therefore, kittens should have their temperature taken in a cat friendly manner (eg, ear thermometer; Figure 14a) during kitten visits.

FIP commonly leads to increased vascular permeability, vessel fluid leakage and development of protein-rich effusions.[3,67,84] Effusion is the most typical change in cats with FIP.[3,88,92] In one study of 224 cats with confirmed FIP, 78% of the cats had effusions.[3] In another study of 127 cats suspected to have FIP, 86% had effusions, with 92/109 having ascites and 11/109 pleural effusion.[92] By the same token FIP is one of the most common causes in cats presenting with effusion. In one study involving 197 cats with effusion, 41% of cases had FIP,[96] while in a more recent retrospective study involving 306 cats diagnosed with pleural effusion of established etiology at a university hospital, only 9% of cats had FIP.[97]

Effusion can occur in various forms – ascites (most common, often with abdominal distension; Figure 12), pleural effusion (dyspnea, tachypnea and muffled heart sounds may be observed), pericardial effusion or, rarely, scrotal effusion.[3,28] In a study of pleural effusions, FIP and trauma were found to be the two most common causes in kittens and young cats.[98]

FIP can cause pyogranulomatous lesions and masses. Clinical signs depend on which organ(s) are affected, with kidneys, liver, intestines (including local lymph nodes), brain and eyes most commonly involved.[46,66,88,99]

The many faces of FIP

Non-specific manifestations



Figure 2 Kitten from a rescue group showing lethargy (listlessness), a common early sign of FIP. LIkewise, failure to thrive or unthriftiness is a frequent complaint in a kitten or young cat with FIP. This kitten eventually developed seizures from neurological FIP. *Courtesy of Julie Jacobs*



Figure 3 Male Ragdoll with a history of anorexia, fever and weight loss of 2 lb (0.9 kg) over 2 weeks, as well as effusion, caused by FIP. *Courtesy of Stacey DeVaney*



Figure 4 Female Oriental Shorthair from a cattery, showing significant weight loss. Jaundice and effusion were also present. *Courtesy of Lisa Callaway*

Neurological manifestations

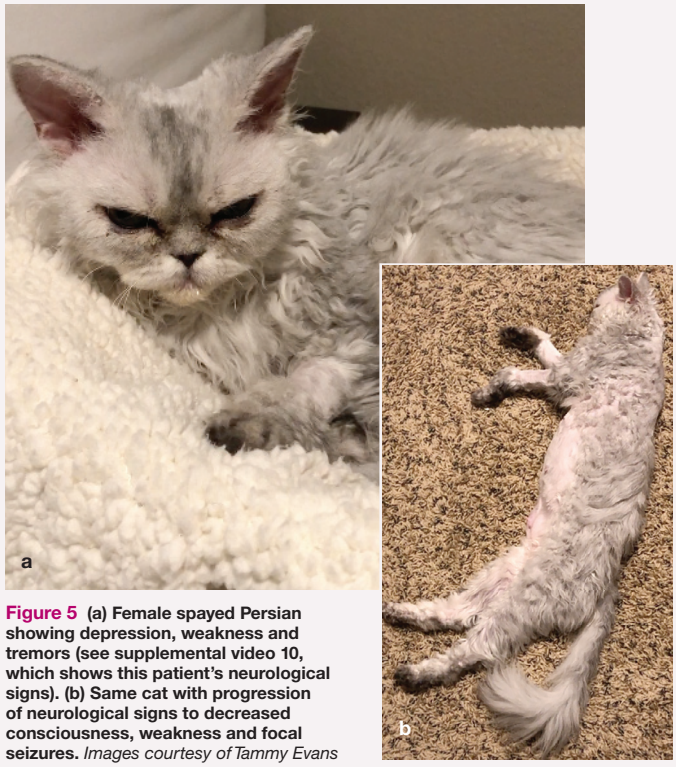

Figure 5 (a) Female spayed Persian showing depression, weakness and tremors (see supplemental video 10, which shows this patient's neurological signs). (b) Same cat with progression of neurological signs to decreased consciousness, weakness and focal seizures. *Images courtesy of Tammy Evans*



Figure 6 Cortical blindness in a male Bengal manifesting as bilateral dilated pupils. *Courtesy of Glenn Olah*



Figure 7 Five-year-old male castrated domestic shorthair cat with non-effusive FIP presenting as progressive weight loss, anemia and development of blindness. The cat was PCR positive on FNAs of kidney, liver, spleen and MLNs. *Courtesy of Matthew Kornya*

Continued on page 912

Continued from page 911

Ocular manifestations



Figure 8 **Oriental Shorthair with anterior uveitis, and corneal edema due to development of glaucoma.** *Courtesy of Lisa Callaway*



Figure 9 **Weight loss and progression of neurological signs accompanied the presence of anisocoria in this 12-year-old male neutered domestic shorthair cat.** *Courtesy of Glenn Olah*

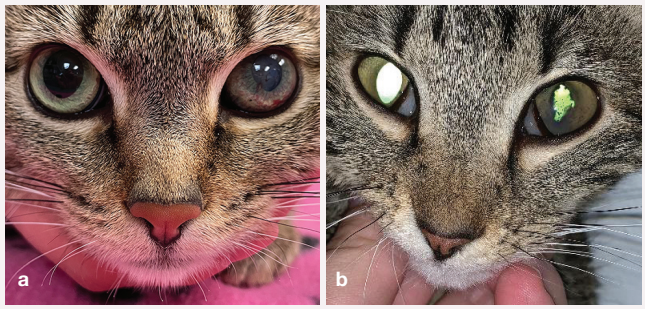

Figure 10 **(a,b) Two cats demonstrating subtle differences in the clinical presentation of anterior uveitis caused by FIP: iris color changes, haziness in the anterior chamber (hypopyon or hyphema) and lesion(s) (keratic precipitates) in the cornea. The young cat in (b) has additional evidence of irregular pupils, which can occur with anterior uveitis caused by FIP. Repeated ophthalmoscopic examinations are indicated in difficult-to-diagnose FIP cases.** *Images courtesy of Marybeth Rymer (a) and Haley Batemen (b)*

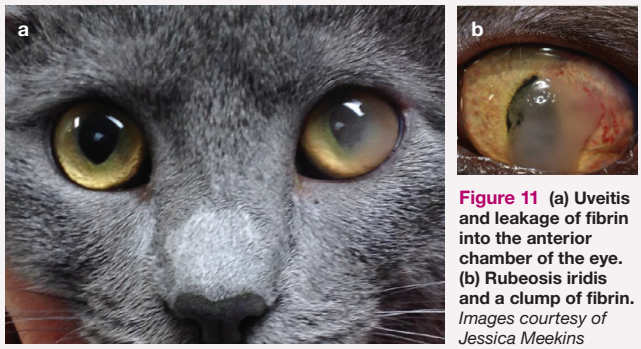

Figure 11 **(a) Uveitis and leakage of fibrin into the anterior chamber of the eye. (b) Rubeosis iridis and a clump of fibrin.** *Images courtesy of Jessica Meekins*

Abdominal effusion



Figure 12 **(a,b) Cat with abdominal effusion (ascites) presenting with abdominal distension, weight loss and decreased muscle mass. This patient is shown in supplemental video 11.** *Images courtesy of Stephanie Newton*

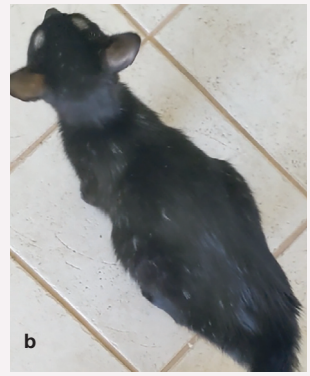

Dermatological manifestations

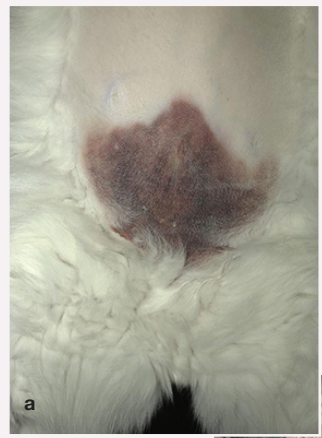

Figure 13 **Ventral inguinal area of an 8-year-old male neutered domestic shorthair cat with significant dermal vasculitis and neutrophilic splenitis that later developed effusion and was diagnosed with FIP. Cats with skin changes can be difficult-to-diagnose FIP cases. These images show the initial (a) and later (b) presentation of the vasculitis.** *Courtesy of Matthew Kornya*

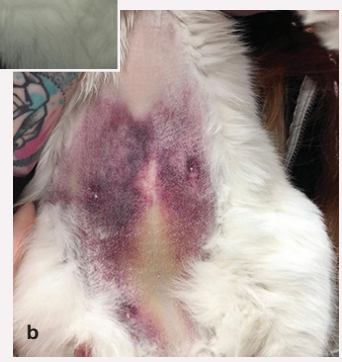

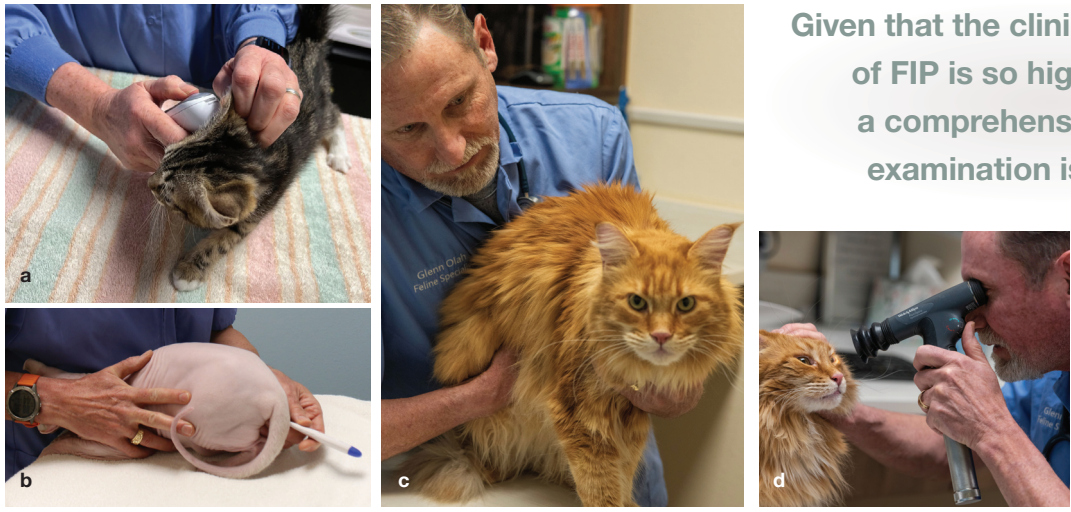

Given that the clinical presentation of FIP is so highly variable, a comprehensive physical examination is essential.

Figure 14 **Essential components of a comprehensive physical examination. (a,b) Fever is one of the earliest non-specific signs of FIP. A temperature should be measured during routine visits in a cat friendly manner (eg, using an ear thermometer); if elevated, a rectal thermometer is used to confirm the existence of fever. (c) Palpation of the abdomen is an essential part of the physical examination for detecting enlarged MLNs, or nodular irregularities on the surface of kidneys or liver due to pyogranulomatous lesions. In addition, abdominal effusion, which is common in cats with FIP, can be noted by the presence of a fluid wave during this procedure. (d) Ocular involvement can be subtle yet creates a number of different changes including keratic precipitates, anterior and/or posterior uveitis, anisocoria and retinal detachment. A full optthalmic examination should be incorporated into the physical examination to obtain a diagnosis of FIP.** *Image (a) courtesy of Dianne Brown; images (b), (c), and (d) courtesy of Glenn Olah*

Pyogranulomatous lesions can be detected upon abdominal palpation as masses (eg, enlarged mesenteric lymph nodes [MLNs]) or palpable nodular irregularities on the surface of normal-sized or enlarged kidneys or liver (Figure 14c).[46,66]

When gastrointestinal signs occur in cats with FIP, this can pose a particular diagnostic challenge. These cats can present with a history of vomiting, diarrhea or constipation, and commonly do not have a fever. MLN enlargement occurs due to necrogranulomatous lymphadenitis,[100,101] or solitary mural intestinal lesions of the ileocecocolic junction or the colon with associated regional lymphadenopathy.[102] It can be difficult to differentiate these lesions from neoplasia,[100] mycobacteriosis[103] or toxoplasmosis.[104] Moreover, these intestinal tract manifestations can cause protein-losing enteropathy and result in low total protein and globulin values – the opposite of what would be expected in a cat with FIP.

The nervous system (eg, brain, spinal cord or meninges) is commonly affected, with neurological signs reported in up to 30% of cats with FIP in some studies.[105,106] Neurological sequelae are reflective of the neuroanatomic localization and can be focal, multifocal or diffuse.[28,107] In one study,[99] 48% of cats had FIP-induced meningoencephalitis; in another study,[108] 8% of cats had myelitis caused by FIP and, in 56% of cats with neurological FIP, the lesions were multifocal. Clinical signs can include seizures, abnormal mentation or behavior, abnormal postural reflex reactions, ataxia, hyperesthesia, nystagmus, anisocoria/dyscoria, cranial nerve deficits or cortical blindness (Table 2).

When gastrointestinal signs occur in cats with FIP, this can pose a particular diagnostic challenge.

Ocular FIP manifests as unilateral or bilateral uveitis and/or chorioretinitis.[88,109,110] In two studies of uveitis, FIP was a common cause, diagnosed in 16% of cats.[111,112] Aqueous flare, hyphema, hypopyon, fibrinous exudate and keratic precipitates within the anterior chamber may be detected during ophthalmic examination (Figures 10 and 11).[75,85] Chorioretinitis can present as retinal perivascular cuffing due to inflammatory cell infiltrates or as focal to diffuse subretinal detachment.[110,111] Since clinical signs of FIP can change over time, new ocular changes can arise, and therefore repeated ophthalmoscopic examination is indicated in difficult-to-diagnose cases.[28]

Other presentations of FIP include dermatological changes. These can manifest as multiple non-pruritic or pruritic nodules or papules[113–116] caused by pyogranulomatous necrotizing dermal phlebitis or vasculitis (Figure 13). Skin fragility syndrome has also been reported.[117] Priapism has been described as a result of granulomatous changes in tissues surrounding the penis.[118]

Another example of a difficult-to-diagnose case is a cat that presents with glomerulonephritis caused by FIP-associated immune complexes, without any other signs of FIP.[119]

Differential diagnoses

Due to the range of clinical signs and pathological manifestations of FIP, exclusion of differential diagnoses is an essential part of the diagnostic process (Table 3). An example of a case of mycobacteriosis – a potentially challenging differential diagnosis – is provided as supplemental file 12; the veterinarian was concerned about FIP, until cytology confirmed *Mycobacteria* species.

Diagnostic testing

A good understanding of each diagnostic test's sensitivity, specificity, predictive value, likelihood ratio (LR) and diagnostic accuracy is important when diagnosing FIP; these are common statistical terms used to describe how accurately a diagnostic test can determine whether a cat has FIP (see box). Sensitivity, specificity and LRs are not influenced by the prevalence of disease in the studied population, while positive (PPVs) and negative predictive values (NPVs) are influenced by prevalence.[121] PPVs will be higher when the prevalence of disease is high and lower when prevalence is low,[123] and predictive values should not be applied to different populations of cats unless it is known that the prevalence of the disease is similar between these populations. If the prevalence of disease is known, a high PPV signals a good chance a cat with a positive test result has FIP. In a highly fatal disease such as FIP, the specificity of the diagnostic test is more important than the test's sensitivity since it will help prevent euthanasia of cats misdiagnosed with FIP.[122]

Common statistical terms used when describing various diagnostic tests for FIP[121,122]

Sensitivity	Test's ability to recognize cats with FIP
Specificity	Test's ability to recognize cats without FIP
Likelihood ratio (LR) or expected test result in cats	(With FIP)/(Do not have FIP) Not influenced by disease prevalence Good diagnostic tests have LR+ >10 or LR– <0.1
Overall test accuracy	(True positives + True negatives)/ Total number of test results
Positive predictive value (PPV)	Probability cat with positive test result has FIP based on disease prevalence in population examined
Negative predictive value (NPV)	Probability cat with negative test result does not have FIP based on disease prevalence in population examined

Table 3 Potential differential diagnoses for FIP[85,120]

Disease/condition	Comparison and clinical considerations
Septic peritonitis/pleuritis	Often these cats are sick, depressed and have fever. Septic effusions are yellow to tan in color and sometimes foul-smelling. Effusions contain high cell counts, and cytology is characterized by degenerative neutrophils and intracellular bacteria. Culture can reveal bacterial infection
Neoplasia (eg, lymphoma)	Lymphoma can involve multiple organs or lymph nodes (like FIP, also affecting younger cats). Other neoplasms are predominantly present in older cats. Cytology can reveal neoplastic cells. Ultrasound-guided aspirates or biopsies of affected tissues may be needed for diagnosis
Toxoplasmosis	Less commonly seen than FIP in cats. Can involve multiple organs and cause signs such as gastrointestinal (diarrhea), ocular, pancreatic, liver and neurological disease. Diagnosis is obtained by finding tachyzoites in samples, or by demonstration of antibodies with high immunoglobulin (Ig)M or rising IgG titers
Pancreatitis	Cats with pancreatitis can exhibit anorexia, jaundice, fever and weight loss. Abdominal effusion can be present as a non-septic exudate, often with a high cell count of non-degenerate neutrophils. Abdominal ultrasound and/or measurement of feline pancreatic lipase immunoreactivity can detect pancreatitis
Lymphocytic cholangitis	Generally this is more chronic in nature than FIP. Liver enzymes (such as alkaline phosphatase [ALP] and alanine aminotransferase [ALT]) are more likely elevated. Jaundice/hyperbilirubinemia can be present. Lymphocytic cholangitis can be associated with inflammatory bowel disease and/or pancreatitis. Aspirates of bile or liver and/or histopathology of liver tissue samples can be diagnostic
Congestive heart failure	Can lead to effusion, most commonly a modified transudate. Cats with congestive heart failure do not typically have a fever. Heart murmur and/or gallop rhythm can be present. Cytology shows a very low cell count. Echocardiography can confirm the diagnosis
Mycobacteriosis	Fever, lymphadenopathy, respiratory signs, abdominal masses and uveitis can occur with *Mycobacteria* species infections. Mycobacterial cases do not usually present with severe hyperglobulinemia or a reduced A:G ratio, as seen with FIP. Cytology can demonstrate (acid-fast) bacteria in tissue samples. PCR and culture can be diagnostic
Trauma	Effusions caused by trauma are usually hemorrhagic and can be differentiated from FIP effusions by cytological analysis

When FIP is a differential diagnosis, typical baseline laboratory work includes a complete blood count, serum biochemistry, urinalysis and FeLV/FIV testing. While not pathognomonic, many cats with FIP will have a mild non-regenerative anemia, lymphopenia, hyperbilirubinemia, hyperglobulinemia[3,83] and an albumin to globulin ratio (A:G) <0.4,[3,67,123] and increased serum amyloid A and alpha-1-acid glycoprotein (AGP) concentrations.[79,124] Other clinicopathological abnormalities can be present depending on the organ system affected (see Tables 4 and 5 for a summary of diagnostic testing).

Effusion analysis

Multiple studies using different testing modalities have found that diagnostic accuracy is highest with effusion analysis, so fluid should be analyzed whenever available (see box of tips below). If there is no evidence of effusion, either overtly or via imaging, then it becomes much more difficult to diagnose FIP ante-mortem.[78,80]

Some FIP cases, however, can be challenging to diagnose even when effusion is present. While effusion caused by FIP is typically yellow and sticky in consistency (Figure 15), some cats have effusions that are more pink-tinged or watery/non-sticky.

Moreover, the location of effusions can be unexpected. For example, intact male cats might only present with scrotal effusion and enlargement due to a serositis involving the tunica vaginalis of the testes.[127] Pericardial effusions occasionally occur without effusions in other body cavities.[70,128]

In a highly fatal disease such as FIP, the specificity of a diagnostic test is more important than the sensitivity.

Typically, FIP effusions contain high protein concentrations and low white blood cell counts and, thus, vary in classification between a modified transudate or exudate, depending on the total protein concentration and total cell count.[28] However, some cats with FIP can have very high cell counts in the effusion (eg, secondary bacterial peritonitis). Even chylous effusions have occasionally been reported in cats with FIP.[71] Effusions sometimes clot upon exposure to air. Gentle warming in a water bath can aid dissolution of a clot to obtain fluid for further analysis.

Laboratory analysis will typically reveal a protein content >35 g/l,[9] an A:G ratio <0.4 and

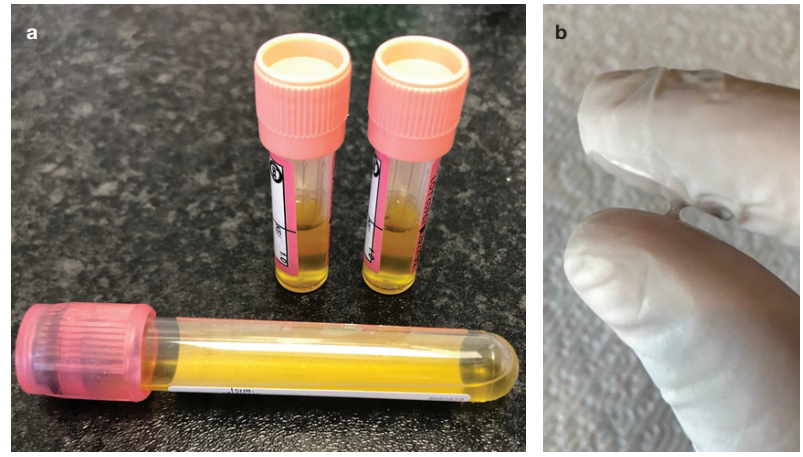

Figure 15 **(a) Abdominal effusion due to FIP collected for sample analysis. (b) Initial assessment of an effusion sample due to FIP. The yellow color and sticky consistency (reflecting the high protein concentration in the fluid) is typical.** *Images courtesy of Emi Barker (a) and Matthew Kornya (b)*

Helpful tips

How to prepare diagnostic cytology slides from an effusion

Important information to keep in mind:

- Place an adequate amount of sample in an ethylenediaminetetraacetic acid (EDTA) tube.
- Always use new, clean microscope slides.
- Change each stain setup at regular intervals, as per the manufacturer's directions.
- Do not heat-fix the slide, but allow the sample to air dry completely before staining.

Examine the color/turbidity of the effusion:

- If it is clear with minimal turbidity, a concentrated specimen will need to be prepared by centrifuging the fluid at 165–360 *g* for 5 mins. This can be achieved in a centrifuge with a radial arm length of 14.6 cm by centrifuging the fluid at 1000–1500 revolutions per minute (rpm). After centrifugation, most of the supernatant is poured off, leaving only about 0.5 ml of fluid with the pellet in the bottom of the tube. The pellet is then resuspended in the remaining 0.5 ml of fluid by gentle agitation, a drop of the suspension is placed on the slide, and a routine pull smear or squash preparation is made.
- If the fluid is turbid, a direct smear can be made without centrifugation by placing a drop of the fluid on a slide and using either a pull smear or squash preparation technique.

Stain the slide:

- Use a Romanowsky-type stain such as Diff-Quik.
- Follow the manufacturer's directions for staining. Note that dipping of slides has been shown to enhance staining (vs passive immersion of slides).
- After staining, rinse the slide with water at room temperature for 20 s.
- Place the slide in a vertical position and allow to air dry.

Examine the slide using a microscope (x 10 or x 20 objective) to verify:

- An adequate number of well-preserved cells for evaluation.
- That the sample has been appropriately stained by identifying cells with familiar morphology and staining characteristics (eg, a peripheral blood cell such as a neutrophil, which is present in most samples).

The information in this box is based on references 125 and 126

Cytology of effusions and tissue samples in cats with FIP and common differentials

FIP

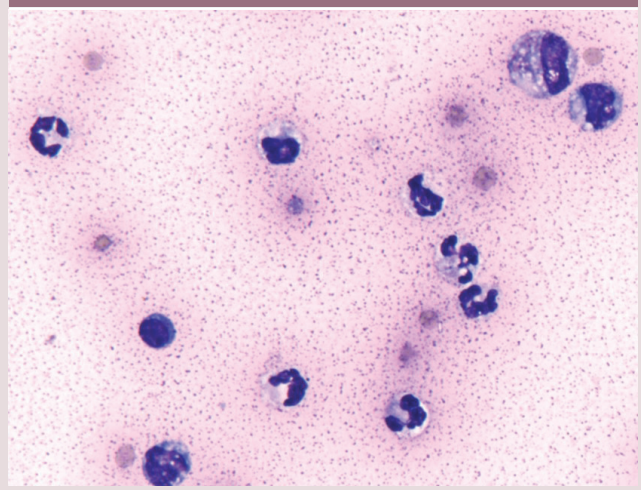

Figure 16a FIP (effusion): mixed cell population (non-degenerate neutrophils, macrophages and one lymphocyte) dispersed with a few erythrocytes in a granular eosinophilic proteinaceous background commonly observed in FIP effusions. Modified Wright stain, x 100

Splenic mast cell tumor

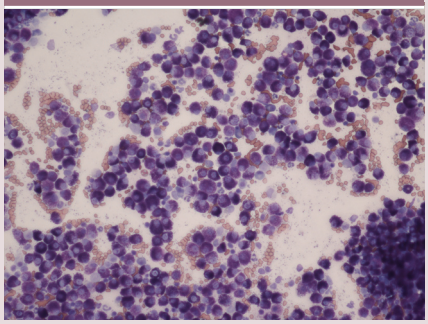

Figure 16b Splenic mast cell tumor: the mast cells are well differentiated with numerous purple-staining metachromatic granules that often obscure the nucleus. Splenic FNA, Wright-Giemsa stain, x 20

Septic peritonitis

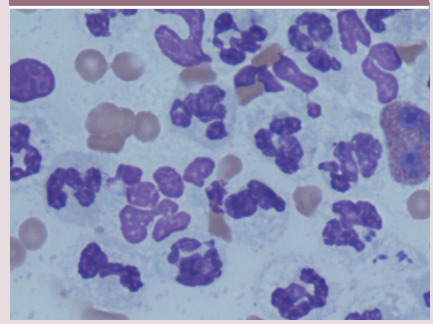

Figure 16c Septic peritonitis (effusion): there is an abundance of neutrophils present; some are swollen with dispersed nuclear chromatin, others have cytoplasmic vacuoles with small rod-shaped bacteria within the cytoplasm. Cytospin preparation, Wright-Giemsa stain, x 100

Mixed thoracic fluid

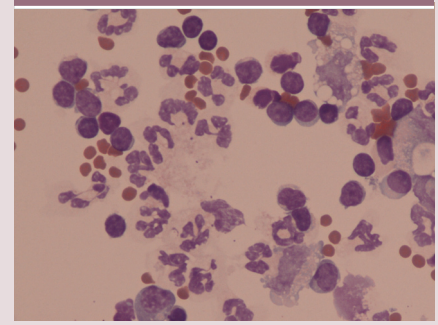

Figure 16d Mixed thoracic fluid (circulatory): there is a mixture of cells present, including small and intermediate sized lymphocytes, neutrophils, macrophages and red blood cells. The vacuolated macrophages exhibit erythrophagy. Cytospin preparation, Wright-Giemsa stain, x 50

Cryptococcosis

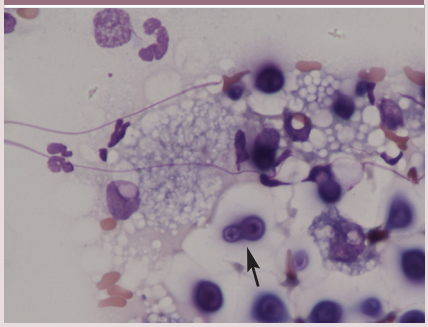

Figure 16e Cryptococcosis: this is an impression smear of a mass on the neck of a cat; there are macrophages with fewer neutrophils, a plasma cell and many yeast organisms, some with the large capsule typical of *Cryptococcus* species. One organism (arrow) exhibits the narrow-based budding seen with this yeast. Wright-Giemsa stain, x 50

Lymph node (normal)

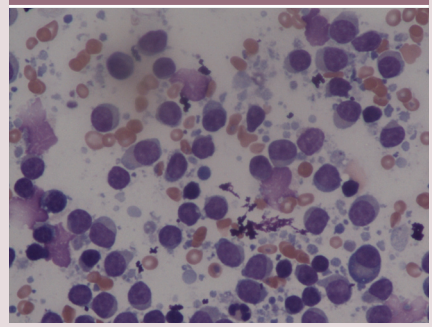

Figure 16f Normal lymph node: there is a mixed lymphoid population present in this FNA of a lymph node. Small lymphocytes are predominant but plasma cells, lymphoblasts, nuclear debris and lymphoglandular bodies are present, as well as occasional macrophages. Wright-Giemsa stain, x 50

Intestinal lymphoma

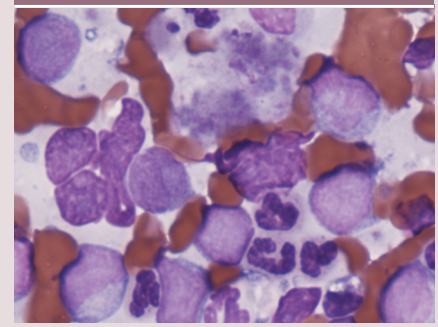

Figure 16g Intestinal lymphoma (effusion): this is a large cell variant of lymphoma with numerous lymphoblasts; small lymphocytes and neutrophils are also present. Cytospin sediment preparation, Wright-Giemsa stain, x 100

Images courtesy of Sally Lester (a–f) and Christopher Lanier (g)

a cell count <5 x 10^9 cells/l. Effusion protein electrophoresis does not add much value if total protein and albumin are measured routinely, provided the globulin concentration (total protein minus all albumin) and A:G ratio are calculated. One study reported that the AGP level was high in FIP effusions (>1550 µg/ml), with a sensitivity and specificity of 93%, but an FIP diagnosis was not always confirmed by immunostaining or histopathology.[129] Immunocytochemistry (ICC) of the cell pellet for FCoV is relatively high in sensitivity, but the specificity is moderate, with false-positive results occurring.[130] (See later discussion on 'Detection of viral antigen'.)

Cytology and bacterial culture can play an important role in differentiating FIP from other causes of effusion. Examples of cytology samples obtained from effusions and tissues are illustrated in Figure 16, highlighting the importance of this diagnostic technique. Generally, cytology of FIP effusions shows pyogranulomatous inflammation with macrophages, non-degenerate neutrophils and very few lymphocytes.[80] This contrasts, for example, with neutrophilia, toxic neutrophils and intracellular bacteria present on a cytological specimen, which would point toward a bacterial peritonitis/pleuritis; or neoplastic cells, such as large lymphoblasts with prominent nucleoli, which would indicate lymphoma. The box on page 915 contains helpful tips for preparing diagnostic cytology slides in-house.

The Rivalta's test is a simple, quick and inexpensive diagnostic tool for examining effusions.[78,131] It is a valuable method to rule out FIP, especially when there are cost concerns, such as in shelter situations. The test is performed by adding a drop of effusion to a slightly acetic solution (see box of helpful tips). High protein content and the presence of inflammatory mediators – characteristics of effusions caused by FIP – will cause the drop to precipitate, indicating a positive test result (Figure 17). If the drop dissipates, this is considered a negative test result. Effusion storage for up to 3 weeks does not influence test results. However, test result interpretation can be challenging due to subjectivity and is dependent on the experience of the clinician.[131]

In earlier studies, the Rivalta's test demonstrated a high sensitivity and specificity for the diagnosis of FIP.[78,96] However, in a large study of 851 cats, sensitivity and specificity were lower (91% and 66%, respectively), although the NPV was still high and the PPV reached almost 90% in cats less than 2 years of age.[132] This means that a negative Rivalta's test result makes FIP very unlikely. A positive Rivalta's test result increases the suspicion of FIP, especially in a young cat; however, this must be confirmed with other tests, as positive results can also occur in cats with bacterial peritonitis/pleuritis or lymphoma.[132] Fluid cytology and bacterial culture can help discriminate between these causes.[133]

Helpful tips

How to perform the Rivalta's test*

- Mix 8 ml of distilled water at room temperature and 20 µl (1 drop) of 100% acetic acid in a plastic test tube (volume 10 ml).
- Carefully layer 20 µl (1 drop) of the effusion on the surface of this solution.
- Observe the behavior of this drop:
  - **A positive test** is indicated by the drop precipitating and either staying attached to the surface of the solution, retaining its shape with a connection to the surface, or floating slowly to the bottom of the tube as a drop or jellyfish-like.
  - **A negative test** is indicated by the drop dissipating (disappearing) and the solution remaining clear.

*Supplemental video 13 shows the Rivalta's test being performed
The information in this box is based on references 78, 96 and 132



Figure 17 Positive Rivalta's test. *Courtesy of Katrin Hartmann, LMU Munich*

A negative Rivalta's test result makes FIP very unlikely. A positive Rivalta's test result increases the suspicion of FIP, especially in a young cat; however, this must be confirmed with other tests.

Diagnostic imaging

Abdominal focused assessment with sonography for trauma, triage and tracking (AFAST) is a first-line screening test that allows the attending clinician to quickly identify whether free fluid and soft tissue abnormalities of the relevant target organ are present. This test is widely used in the emergency setting for the quick detection of free fluid but it also can be used as a point-of-care ultrasound (POCUS) screening in cats suspected of having free fluid associated with FIP. The technique, which involves placement of the ultrasound probe in four different locations on the abdomen, is relatively easy to learn. Moreover, AFAST is a rapid (<3 mins), real-time imaging modality that has low patient impact.[134] Since many cats do not initially present with a noticeable abdominal fluid wave, or their disease transitions from being primarily non-effusive to effusive, serial AFAST examinations are an excellent diagnostic tool for identifying these cases.

Figures 18–21 are positive AFAST images showing anechoic free fluid (alongside each image [a] is an identical, labeled version [b]). Such findings in a cat suspected of having FIP

Positive AFAST images demonstrating anechoic free fluid*

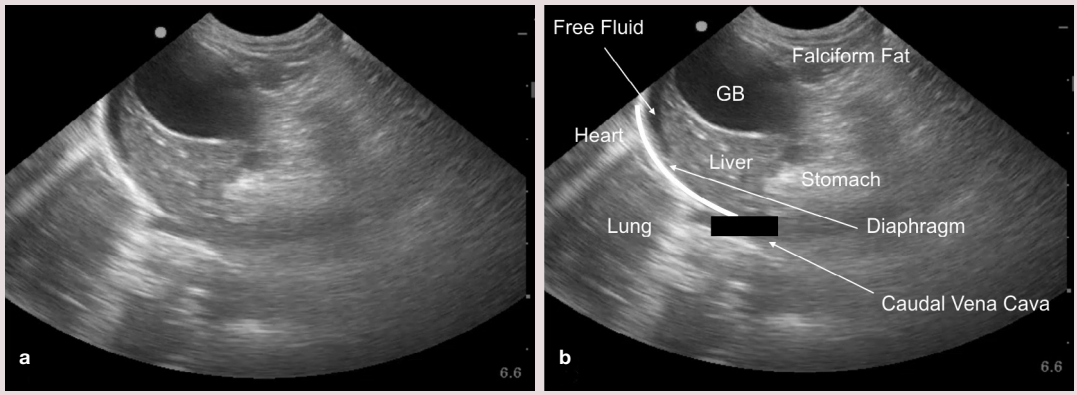

Figure 18 Positive AFAST at the subxiphoid (Diaphragmatico-Hepatic [DH] view) demonstrating a typical anechoic accumulation of free fluid between the diaphragm and liver. By looking cranial to the diaphragm, pleural and pericardial effusion and lung pathology can also be detected

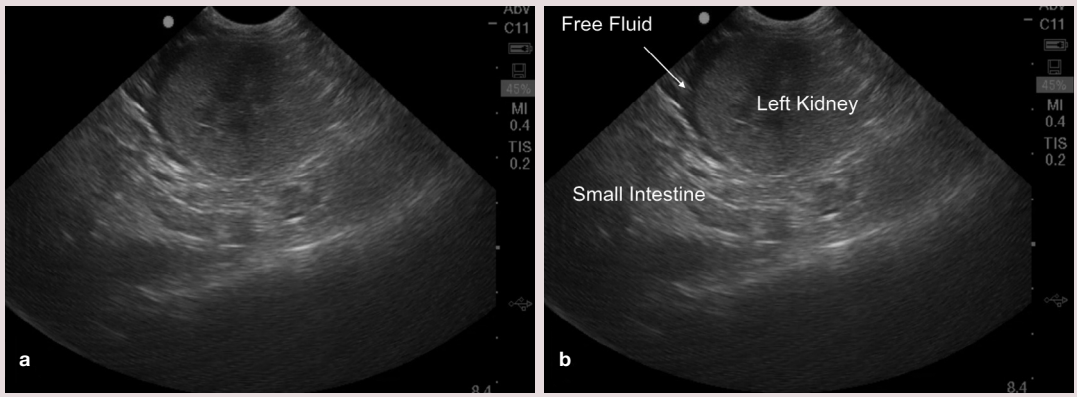

Figure 19 Positive AFAST (Spleno-Renal view) in the region of the costal arch and sublumbar muscles, demonstrating a typical anechoic accumulation of free fluid along the cranial pole of the left kidney and tail of the spleen. The target organs are the left kidney and spleen, although in most cats both kidneys may be seen at this view

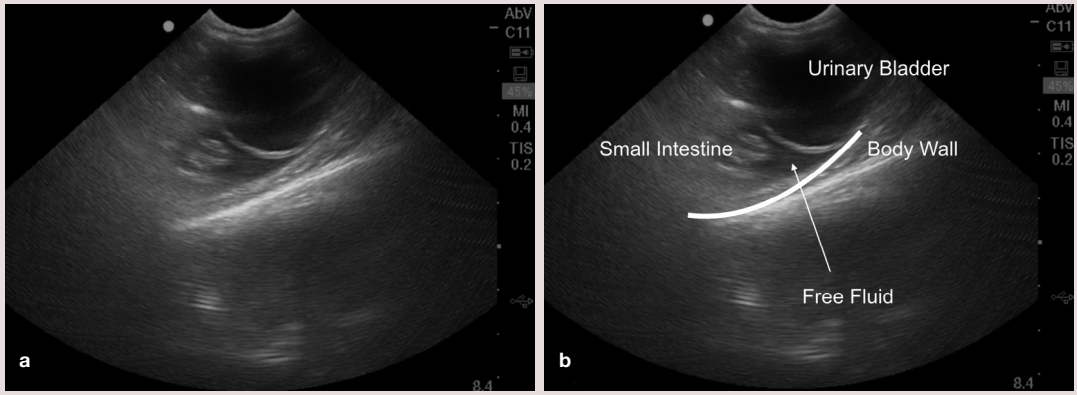

Figure 20 Positive AFAST (Cysto-Colic view [a] with a urine-filled bladder) demonstrating a typical anechoic accumulation of free fluid between the urinary bladder and the body wall in the most gravity-dependent region called the Cysto-Colic Pouch. The target organ is the urinary bladder. Small intestine will also be in view

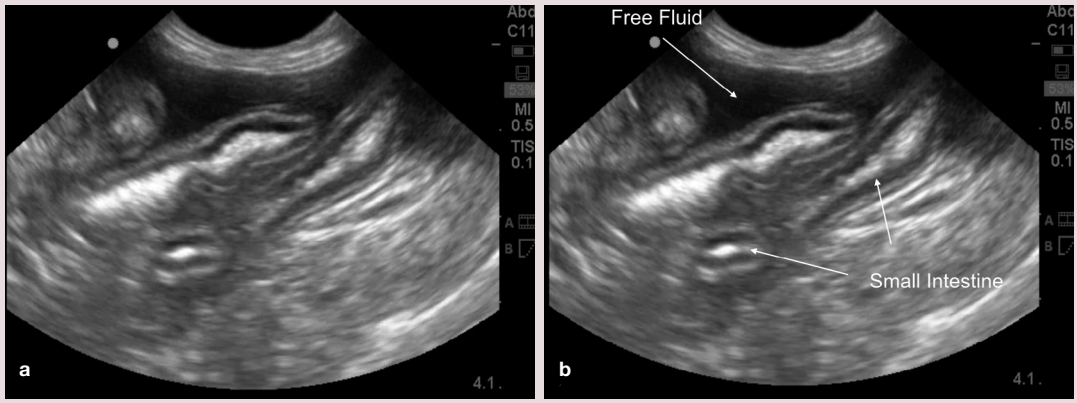

Figure 21 Positive AFAST (Hepato-Renal Umbilical view) at the level of the umbilicus demonstrating a typical anechoic accumulation of free fluid between loops of intestine (arrow), the body wall, and omentum in the most gravity-dependent region called the Umbilical Pouch. The target organs are the small intestine and spleen

*For each figure, (b) is a labeled version of (a). *Images courtesy of, and with permission from, Dr Gregory Lisciandro, Hill Country Veterinary Specialists and FASTVET.com, Spicewood, Texas, USA; and Point-of-Care Ultrasound Techniques for the Small Animal Practitioner, 2nd edition © 2021*[134]

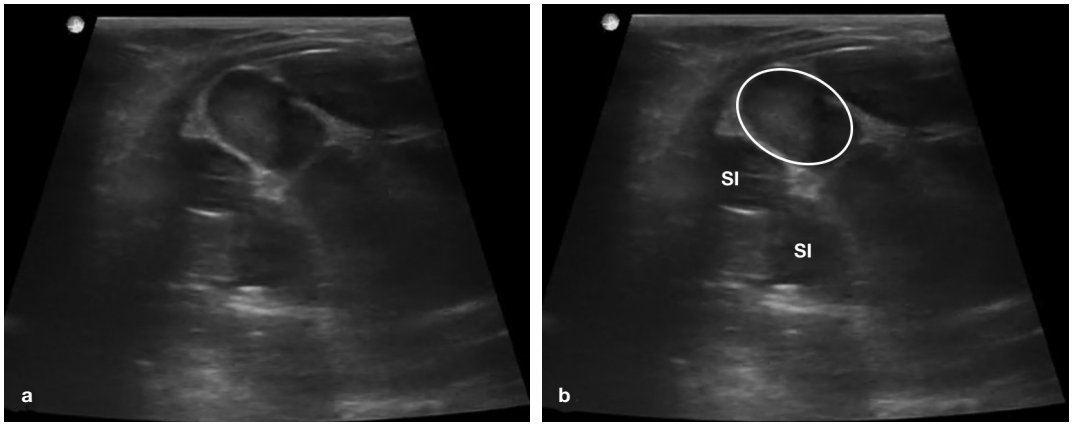

Figure 22 **Mesenteric lymphadenopathy. The hypoechoic structure in the mid-abdomen may be screened for during AFAST and its target organ approach and detected during complete abdominal ultrasound studies. In (a) the image is unlabeled and in (b) labeled with the mesenteric lymph node outlined with an oval and small intestine (SI). Enlargement has been defined by measurements of thickness of being no more than 5 mm; however, some may be considered normal up to 7–8 mm. The ratio of short axis to long axis is another parameter that may be used, with normal <0.5.[135]** *Images courtesy of, and with permission from, Dr Stephanie Lisciandro, Hill Country Veterinary Specialists and FASTVET.com, Spicewood, Texas, USA © 2021*

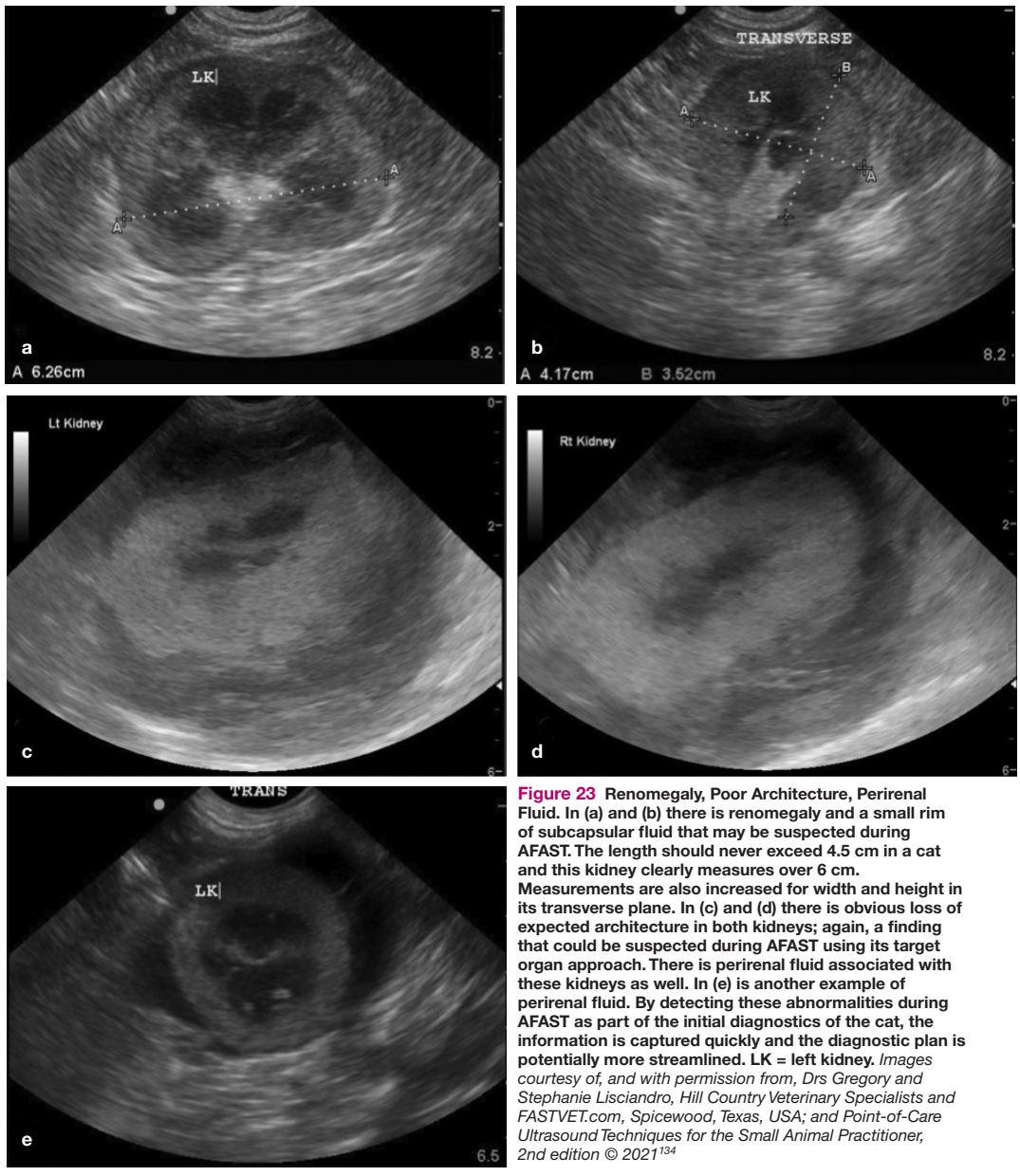

Figure 23 **Renomegaly, Poor Architecture, Perirenal Fluid. In (a) and (b) there is renomegaly and a small rim of subcapsular fluid that may be suspected during AFAST. The length should never exceed 4.5 cm in a cat and this kidney clearly measures over 6 cm. Measurements are also increased for width and height in its transverse plane. In (c) and (d) there is obvious loss of expected architecture in both kidneys; again, a finding that could be suspected during AFAST using its target organ approach. There is perirenal fluid associated with these kidneys as well. In (e) is another example of perirenal fluid. By detecting these abnormalities during AFAST as part of the initial diagnostics of the cat, the information is captured quickly and the diagnostic plan is potentially more streamlined. LK = left kidney.** *Images courtesy of, and with permission from, Drs Gregory and Stephanie Lisciandro, Hill Country Veterinary Specialists and FASTVET.com, Spicewood, Texas, USA; and Point-of-Care Ultrasound Techniques for the Small Animal Practitioner, 2nd edition © 2021*[134]

Many cats do not initially present with a noticeable abdominal fluid wave, or their disease transitions from being primarily non-effusive to effusive. Serial AFAST examinations are an excellent tool for identifying these cases.

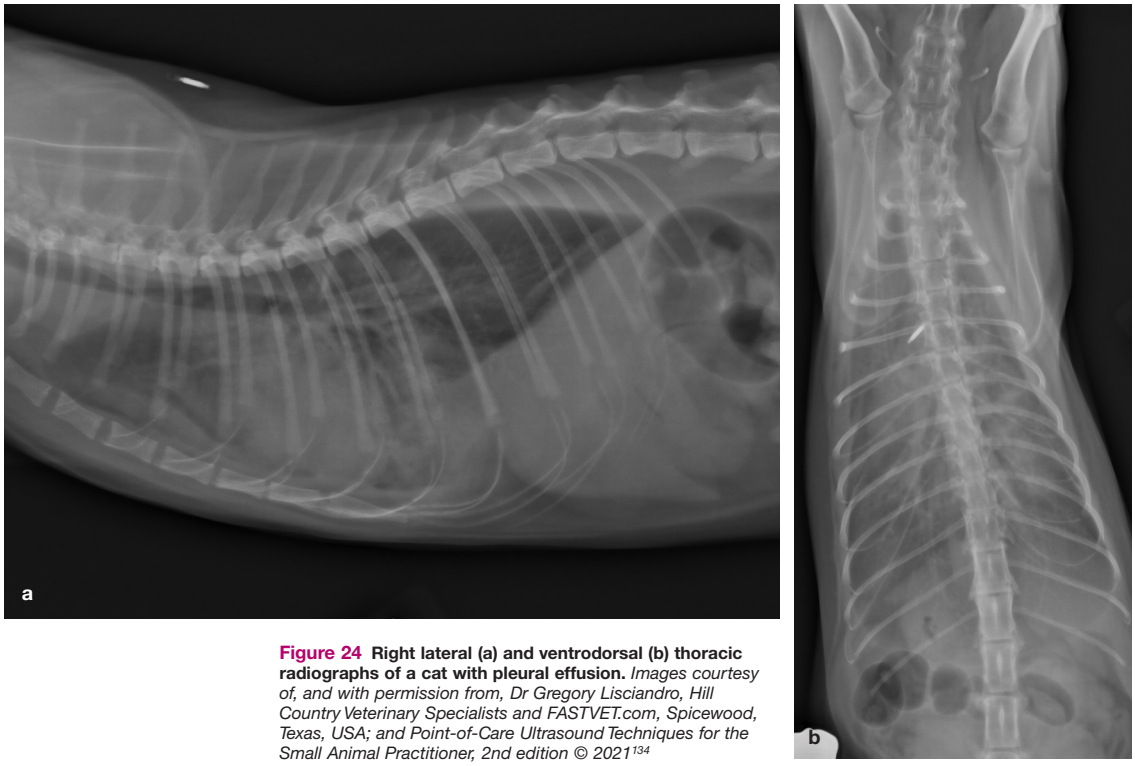

Figure 24 Right lateral (a) and ventrodorsal (b) thoracic radiographs of a cat with pleural effusion. *Images courtesy of, and with permission from, Dr Gregory Lisciandro, Hill Country Veterinary Specialists and FASTVET.com, Spicewood, Texas, USA; and Point-of-Care Ultrasound Techniques for the Small Animal Practitioner, 2nd edition © 2021*[134]

are an indication for immediate fluid sampling and analysis.

As a screening test for free fluid and soft tissue abnormalities, AFAST can be utilized as both a monitoring tool and an extension of the physical examination.[134] (See supplemental file 14 for specific instructions.) Further, if free fluid is not detected and the history, signalment and physical examination findings are highly suggestive of FIP, then a complete abdominal ultrasound examination is indicated. There have been limited studies investigating the diagnostic utility of abdominal ultrasound in the ante-mortem diagnosis of FIP. A retrospective study that reviewed abdominal ultrasonographic results associated with FIP in 16 cats demonstrated that, when FIP is under consideration, certain findings such as abdominal lymphadenopathy (mesenteric [Figure 22], splenic, etc), renal architectural changes, presence of effusion (peritoneal or retroperitoneal [Figure 23]) and intestinal changes should elevate FIP to the top of the differential diagnosis list.[82]

Depending on the clinical presentation, physical examination findings, the imaging equipment available and the veterinarian's assessment of the patient's clinical status, thoracic radiographs may be indicated if pleural effusion is suspected (Figure 24). If the cat is extremely dyspneic, a standing lateral or dorsoventral radiographic view is preferable or thoracic POCUS since these cats are at an increased risk for respiratory arrest.

In cases where there is no obvious respiratory distress but fluid is still suspected, thoracic focused assessment with sonography for trauma, triage and tracking (TFAST) should be performed since, as with abdominal effusion, ultrasound is more likely to detect small amounts of fluid (Figures 25 and 26).[85] (See supplemental file 14 for specific instructions.) The AFAST DH view can be combined with the right pericardial site (PCS) TFAST view to identify whether pleural effusion is present.[134] Pericardial effusion has been associated with FIP, but is uncommon.[70] However, while radiography of the thorax is usually diagnostic for pleural effusion, the gold standard for pericardial effusion is cardiac ultrasonography. The entire heart is imaged so that the hyperechoic pericardium is visible. If fluid has accumulated between the heart and the pericardium, the apex of the heart will appear rounded (Figure 27).[134]

AFAST is a first-line screening test that is widely used in the emergency setting for the quick detection of free fluid. It can also be used as a point-of-care ultrasound screening in cats suspected of having free fluid associated with FIP.

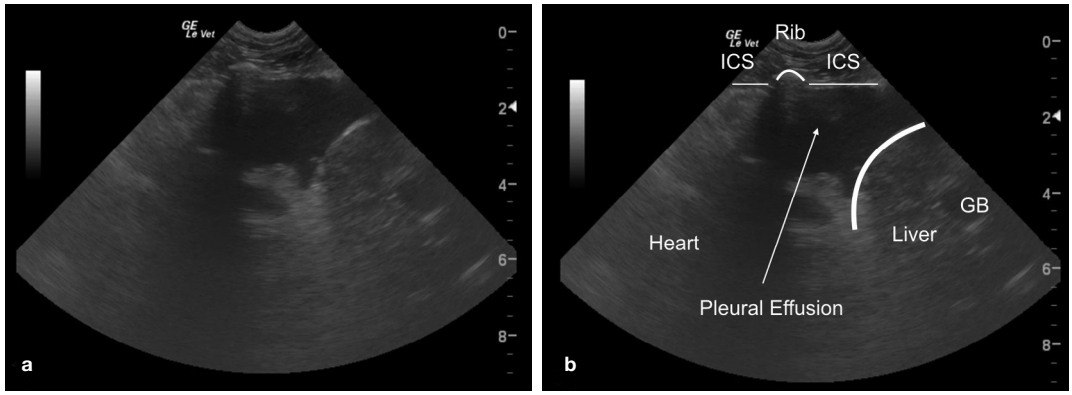

Figure 25 Pleural effusion located in the cardiac diaphragmatic pouch. During the 'TFAST slide', the probe is moved caudally from the heart to the diaphragm where the most gravity-dependent area is located, the cardiac diaphragmatic pouch. *Images courtesy of, and with permission from, Dr Gregory Lisciandro, Hill Country Veterinary Specialists and FASTVET.com, Spicewood, Texas, USA; and Point-of-Care Ultrasound Techniques for the Small Animal Practitioner, 2nd edition © 2021*[134]

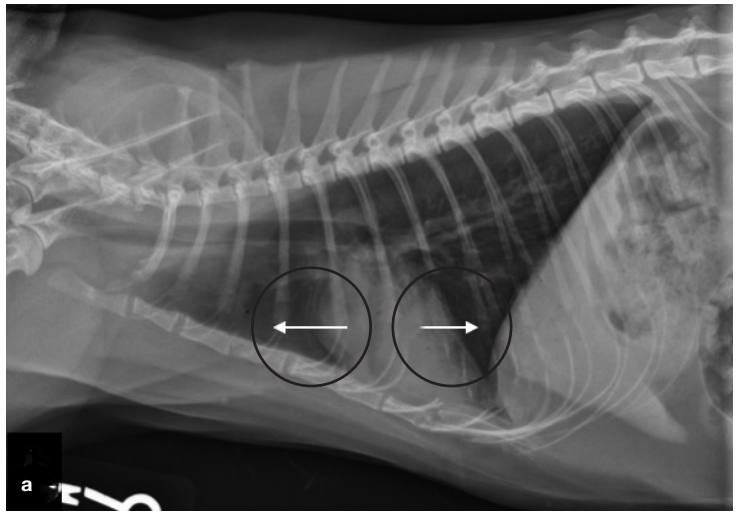

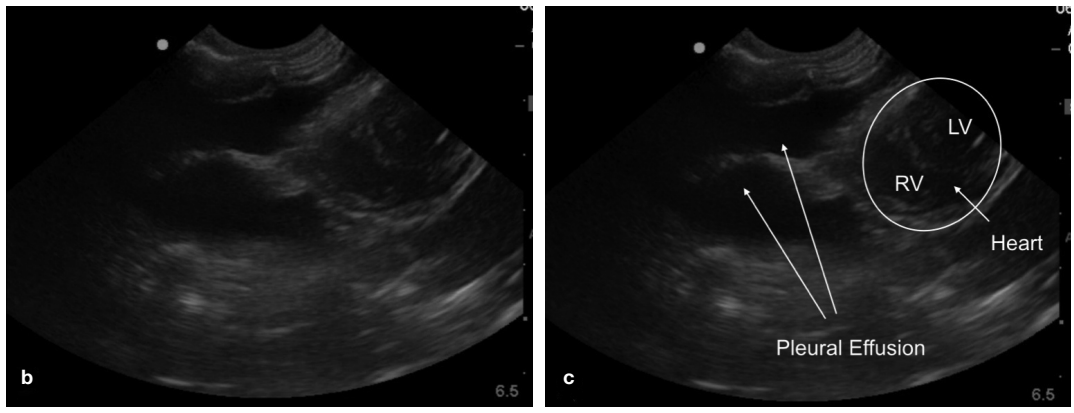

Figure 26 (a,b,c) Pleural effusion located in the cardiac cervical pouch. During the 'TFAST slide', the probe is moved cranially across the heart to the cardiac cervical pouch, which is the most gravity-dependent area in the standing or sternal patient positions and is located cranial to the heart, which is identified by the arrows. *Images courtesy of, and with permission from, Dr Gregory Lisciandro, Hill Country Veterinary Specialists and FASTVET.com, Spicewood, Texas, USA; and Point-of-Care Ultrasound Techniques for the Small Animal Practitioner, 2nd edition © 2021*[134]

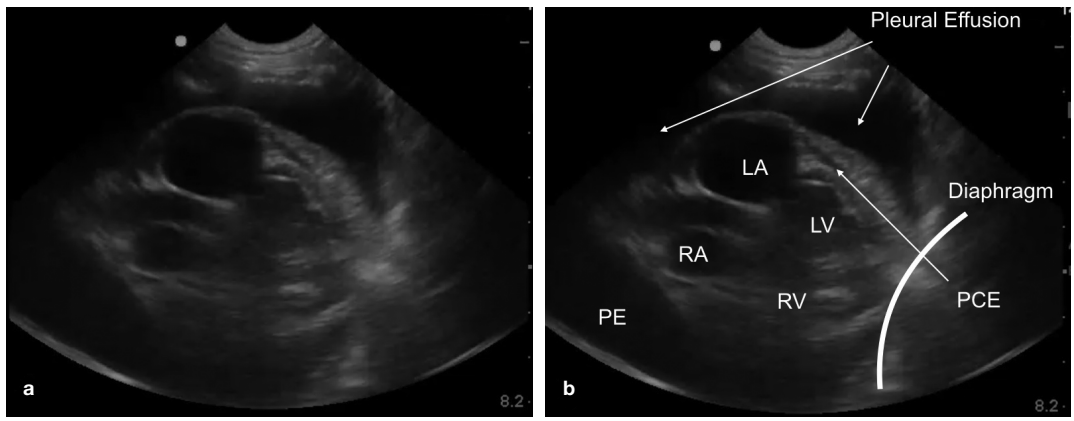

Figure 27 Pleural and pericardial effusion. The entire heart is visible. *Images courtesy of, and with permission from, Dr Gregory Lisciandro, Hill Country Veterinary Specialists and FASTVET.com, Spicewood, Texas, USA; and Point-of-Care Ultrasound Techniques for the Small Animal Practitioner, 2nd edition © 2021*[134]

Histopathology

Histopathology of lesions is quite specific for a diagnosis of FIP, but sampling is invasive or can only be performed post mortem. Generally, sampling of multiple tissues is preferred to improve sensitivity[58] and can include MLNs, small and large intestines, omentum, spleen, kidney and liver.[136] Pathology will typically show vasculitis with perivascular necrosis. Pyogranulomatous lesions can be identified around the vasculature, especially on serosal surfaces.[137,138] Immunohistochemistry (IHC; see later discussion on 'Detection of viral antigen') will reveal FCoV antigen associated with macrophages within the lesions; thus IHC is more specific than histopathology alone[136] and is considered the gold standard for diagnosis.[80]

A cat with suspected FIP is often too sick or debilitated to undergo surgical sample collection for histopathology and IHC. Recent investigations of ante-mortem diagnosis of FIP have used minimally invasive techniques such as ultrasound-guided fine-needle aspiration[58,139,140] or Tru-cut biopsy (TCB) of kidney and liver.[141] One study investigated whether certain combinations of diagnostic tests (histology, IHC and/or nested RT-PCR [RT-nPCR]) performed on TCB samples obtained post mortem could be utilized in making an ante-mortem diagnosis of FIP.[136] Histological lesions previously associated with FIP[88] were found to be present in some organs, but not all; and some cats with organ lesions consistent with FIP had diseases other than FIP. Based on these findings, it was recommended that biopsies be obtained from more than one organ in order to increase the odds of diagnosing FIP.[136] Tips for obtaining a diagnostic FNA are provided in the box.

Helpful tips

How to successfully obtain a diagnostic FNA

- Remove any ultrasound gel from the skin surface prior to fine-needle aspiration.
- Choose a 20–27 G, 2.5–3.8 cm needle (6.3–8.9 cm spinal needle for deeper organs) with a 6–12 ml syringe. Note that larger gauge needles do not necessarily increase the possibility of obtaining a diagnostic sample.
- Different studies vary in terms of which technique is best for a particular organ: aspiration or non-aspiration. Generally the aspiration technique is recommended for the spleen and abdominal lymph nodes, and the non-aspiration technique for the liver and kidneys.
- Aspiration technique – an identical vacuum is generated when the plunger is displaced to the same point in different sized syringes. Hence, the syringe selected should be one that the clinician obtaining the FNA can most easily control.
- Polylysine-coated slides are recommended if performing ICC to ensure cells bind to the slide during processing.
- The needle should be directed in a multi-plane manner to obtain the sample, moving it forward and back in short strokes three or four times. Four or five aspirates should be obtained per sample. The needle should be changed for each aspirate since it has been found that the likelihood of obtaining a definitive diagnosis increases with subsequent needles.
- There are three different methods for making smears depending on the consistency of the aspirate: squash preparation, blood smear and line smear.
- Abdominal lymph nodes: choose a 21 G needle. Abdominal lymph nodes are more likely non-diagnostic compared with subcutaneous.
- Collect a minimum of three non-aspiration samples per lymph node. Lymphocytes are fragile, so use care when making the smear preparation.
- Kidney: choose a 25 G, 1.5–5 cm needle. Diagnostic sensitivity of FNA cytology smear = 42%.
- Liver: Diagnostic sensitivity of FNA cytology smear = 82%.

The information in this box is based on references 48, 54, 56, 57, 70, 78, 80, 85, 124, 136, 141 and 142

Detection of viral nucleic acid

Detection of viral RNA is one way of confirming FCoV as the underlying etiological agent (see box below). Real-time RT-PCR (also referred to as RT-qPCR) for FCoV nucleic acids can be performed on blood, other fluids (eg, effusion, CSF or aqueous humour), and tissue samples or FNAs. However, since less-virulent FCoV can spread systemically in cats without FIP, and PCR methods are very sensitive, the detection of FCoV RNA by RT-qPCR in blood, fluid or tissue is not necessarily specific for a diagnosis of FIP (see box on page 923).[38,122,146,147] One study looked into the diagnostic utility of RT-qPCR of MLN FNAs in cats without effusion and found an overall sensitivity of 90% and specificity of 96.1%.[140] Additionally, it has been shown that the sensitivity of RT-qPCR did not differ significantly between FNAs and incisional biopsies; thus, the more invasive biopsy technique is not mandatory for obtaining sample material for RT-qPCR.[58]

RT-qPCR can indicate the amount of virus in the sample. Cats with FIP generally have higher viral loads than healthy FCoV-infected cats,[60,61,148] meaning that a positive RT-qPCR result with high viral load moves FIP up the list of differential diagnoses. Fluids and fresh tissue are best suited for RT-qPCR, but fixed tissue is acceptable.[149]

Mutations within the S protein gene can also be detected by special *S* gene real-time RT-PCR using specific primers[58,122,150–152] or by

METHODS OF IDENTIFYING FCoV AS THE UNDERLYING ETIOLOGICAL AGENT

- **Direct methods:** An underlying etiological agent of an infectious disease can generally be identified directly by detecting the viral genome using PCR (detection of viral nucleic acid; DNA or RNA) or, in the case of FCoV (an RNA virus), by using real-time RT-PCR (detection of viral nucleic acid) or by detection of viral antigens (viral proteins).
- **Indirect methods:** Identifying an underlying etiological agent can be done indirectly by detecting antibodies against the infectious agent.

Helpful tips

RT-PCR testing

RT-PCR assays involve many steps, which can potentially introduce laboratory error

- The genome of FCoV, an RNA virus, must first be isolated, extracted and purified from the sample.
- The RNA is then reverse transcribed to complementary DNA (cDNA).
- A small segment in the cDNA that encodes an FCoV-specific sequence is then amplified by PCR to produce many copies that can be detected by gel electrophoresis or nucleic acid sequencing.
- The target sequence chosen to be amplified can vary between commercial laboratories, which affects test interpretation (eg, one RT-PCR for FCoV may not be the same as another).

Currently available FCoV real-time RT-PCR testing cannot definitively differentiate between the mutated and non-mutated forms of FCoV

- The real-time RT-PCR for *M* gene assay detects both the FCoV genomic RNA found in serum as well as the subgenomic RNA for expression of the M protein found in tissue samples containing FCoV-infected cellular material. Since the assay can detect FCoV subgenomic RNA, indicating the FCoV had entered and replicated in cells outside the intestinal epithelium, it was initially believed that a positive test result indicated the presence of FIPV. Later studies have demonstrated that both FECV and FIPV can spread systemically, so location-specific testing such as this assay may be inaccurate.[38] Special *S* gene RT-PCRs, using specific primers for detection of *S* gene mutations thought to be specific for FIP, have in later studies also been positive in cats without FIP.

Different types of FCoV RT-PCR tests are available, based on test design

- RT-PCR – conventional and semiquantitative.
- Real-time RT-PCR (also referred to as RT-qPCR) – quantitative and diagnostically more accurate than RT-PCR.*†
- RT nPCR – two-step PCR reaction that first amplifies larger segment in cDNA; product is purified and then smaller segment is amplified. This assay is used only if there is an issue with sensitivity/specificity with the RT-qPCR, and it is not very useful diagnostically if the first-round cDNA needs to be purified.
- 7b-RT-qPCR – this RT-qPCR was developed to quantify the level of FIPV through specific targeting of the 7b accessory gene. Typically, it is run first to verify FCoV presence and then followed by another RT-qPCR to detect mutations.
- Real-time RT-PCR for *M* gene.†
- Real-time RT-PCR detecting *S* gene mutations using specific hydrolysis probes.†
- Real-time RT-PCR followed by sanger sequencing for *S* gene mutations – more specific for detection of *S* gene mutations than special real-time RT-PCR detecting *S* gene mutations using specific primers.

*Preferred for most situations. †Available in commercial laboratories
The information in this box is based on references 50, 60, 88, 92 and 143–145

Both indirect and direct detection methods only indicate the presence of FCoV, and not specifically the mutated virus that leads to FIP.

sequencing after real-time RT-PCR.[60,79,153] For the mutation-specific RT-qPCRs, these typically will be combined into one assay, referred to as multiplexed, for interpretation of results. The assay will involve one PCR amplicon set targeting a conserved region that will detect all FCoV species, and a second set where one of the primers (forward or reverse) is specific at the 3′ end for the mutation being looked for, and the mutation-specific primer will only bind if the mutation is present. It will not bind to sequences other than the mutation being looked for, so there will be several possible outcomes for the diagnostic:

- FCoV RT-qPCR–/spike mutant RT-qPCR– (eg, no FCoV infection);
- FCoV RT-qPCR+/spike mutant RT-qPCR– (eg, FCoV infection, non-spike mutant);
- FCoV RT-qPCR+/spike mutant RT-qPCR+ (eg, FCoV infection, spike mutant); and
- FCoV RT-qPCR–/spike mutant RT-qPCR+ (eg, something is wrong with the assay).

A positive RT-qPCR result with high viral load moves FIP up the list of differential diagnoses.

In a recent study, FCoV containing *S* gene mutations was found in at least one body fluid or tissue in all cats with FIP, but the distribution varied from cat to cat, hence a recommendation that multiple samples be analyzed to increase sensitivity.[58] The specificity of detection of *S* gene mutations for FIP is highly controversial. While specificity of the *S* gene real-time RT-PCR was good in effusion and tissues in some studies, false-positive results have been frequently demonstrated.[122,152,154] The usefulness of the special *S* gene RT-PCR using specific primers has been questioned and detection of *S* gene mutations by sequencing might be more specific for diagnosing FIP. However, even the sequencing approach was not able to improve specificity significantly in a few studies.[60,79]

Detection of viral antigen

FCoV antigen can be detected by staining the antigen within its target cells, fluid or tissue macrophages, using different immunostaining methods. The binding of antibodies to host cell-associated FCoV antigens is subsequently visualized (by IHC, ICC or immunofluorescence [IF]), producing a color change or fluorescence.

FCoV antigen detection in macrophages of affected tissues via immunostaining is highly specific and reliable,[136,155,156] as long as it is performed with appropriate controls and reagents that prevent non-specific binding of anti-FCoV antibodies to the tissues. Hence, it is considered the gold standard method for diagnosing FIP.[28,80,88,136,157] Samples of affected tissues can be taken during exploratory laparotomy, by laparoscopy or ultrasound-guided biopsy, or at necropsy. Although immunostaining cannot differentiate between non-mutated and mutated viruses, the presence of a high amount of antigen, which is necessary for positive staining, indicates high virus replication rates within macrophages – the key event in the pathogenesis of FIP. However, negative IHC results do not exclude FIP because FCoV antigens can be variably distributed within lesions.[58,88,136,141] Ideally, samples should be taken from areas with histopathological changes.

FCoV immunostaining can also be performed on cytology samples from tissues, effusions, CSF or aqueous humour using ICC or IF.

ICC on MLN FNAs has been suggested as a non-invasive method to diagnose FIP, but one study showed only moderate sensitivity of 53% and a false-positive result in a cat with lymphoma.[139] A study comparing the efficacy of FCoV immunostaining in hepatic and renal TCBs and FNAs found that sensitivity in both tissues was poor (24% and 17–31% for hepatic TCBs and FNAs, respectively; 17% and 11–20% for renal TCBs and FNAs, respectively), although combining the two sampling techniques slightly increased sensitivity (to 38% for liver and 14% for kidney samples).[141]

FCoV immunostaining of effusion has had variable sensitivity in different studies, ranging from 57% to 100%.[78,96,130,158,159] False-negative results are possible if the effusion does not contain enough macrophages or if anti-FCoV antibodies mask the FCoV antigen.[78,160] Further, while immunostaining has long been thought to be very specific, false-positive results have occurred in more recent studies. In one study, 2/7 cats with effusion due to other diseases (heart failure and cholangiocarcinoma) had false-positive results by IF.[159] In another study, 8/29 cats with effusions due to other diseases (heart failure in three cats and neoplasia in five cats) tested false positive by ICC.[130] ICC with dual staining for macrophages as well as FCoV antigen might potentially increase specificity.[161]

FCoV antigen detection in macrophages of affected tissues via immunostaining is considered the gold standard for diagnosing FIP.

FCoV immunostaining using ICC was successful in detecting FCoV antigen in the CSF of a cat with neurological FIP.[162] However, one larger study evaluating CSF ICC in cats with and without FIP (with or without neurological signs) found positive results in 17/20 cats with FIP but also in 3/18 cats without FIP (one cat each with mediastinal lymphoma, meningoencephalitis, and hypertensive angiopathy with brain hemorrhage), indicating low specificity.[163] FCoV antigen has also been detected by ICC in aqueous humour samples, with a sensitivity of 64% and specificity of 82%; false-positive results occurred in one control cat with lymphoma and one control cat with pulmonary adenocarcinoma.[130,151]

Detection of anti-FCoV antibodies

Detection of antibodies against an infectious agent is an indirect method of identifying an underlying etiological agent. Anti-FCoV antibodies can be detected by enzyme-linked immunosorbent assay (ELISA), or indirect immunofluorescence antibody (IFA) or rapid immunomigration tests.[164] Due to a lack of standardization among antibody targeting methods, results of different tests and from different laboratories can vary; hence they are difficult to compare, and some can be unreliable. Additional considerations for laboratory test submissions are summarized in the box.

Measurement of anti-FCoV antibodies can be used to detect FCoV infection; however, the

Helpful tips

Laboratory considerations regarding sample analysis

- FCoV is an RNA virus and so it is common for it to mutate during replication. As such, design changes at the probe or primer binding site may affect the sensitivity of PCR testing.
- Check with the laboratory performing the diagnostic test what the sensitivity and specificity are for the particular test.
- Recognize that the diagnostic accuracy of some tests depends directly on the sample being analyzed (eg, real-time RT-PCR run on effusion vs serum).
- Before submitting a sample for any diagnostic test or commercial laboratory profile, be able to answer the questions: why this test and what do the results mean?
- When comparing laboratory test results, make sure the same laboratory and the same testing method are being used, and that the scientific community has validated any RT-qPCR or antibody test. To determine if the laboratory is using a validated test, the clinician should request the study or studies used to validate the testing methodology, which should include the sensitivity and specificity, the antigen used for antibody testing, and the design of the RT-qPCR assay. Normal reference intervals for laboratory parameters may vary from one laboratory to another.

The information in this box is based on references 80, 81 and 85

presence of antibodies is not useful for diagnosing FIP, since antibodies are not only present in cats with FIP, but also in healthy FCoV-infected cats or FCoV-infected cats with other diseases.[78] Thus antibodies against FCoV in feline serum or plasma indicate only that the cat has had contact with FCoV through natural infection or vaccination, with antibodies usually developing on days 10–28 post-infection.[39,165] Although cats with FIP tend to have higher anti-FCoV antibody titers than cats without FIP, there is often no difference in median anti-FCoV antibody titers between healthy cats and cats with FIP.[78] Moreover, negative antibody test results do not rule out FIP, since up to 10% of cats with FIP do not have anti-FCoV antibodies.[78] This percentage was even higher in cats with neurological FIP without effusion.[166]

In addition to blood (serum, PBMCs or plasma), anti-FCoV antibody testing has also been performed on a variety of other sample types including effusion, CSF and aqueous humour. However, the diagnostic value in using these samples is also limited since antibodies can easily leak from the blood into high-protein effusions or cross a disturbed blood–brain barrier.[167] Additionally, negative results can occur in cats with FIP due to binding of antibodies by FCoV, as has been shown for effusion.[164,168] Overall, antibody testing in serum, plasma or any other fluid is not recommended for the diagnosis of FIP.[80]

Overall, antibody testing in serum, plasma or any other fluid is not recommended for the diagnosis of FIP.

Table 4 Routine diagnostic testing for FIP – an overview*

	Test	Typical findings in cats with FIP	Comments
Blood	CBC	Non-regenerative anemia, microcytosis, lymphopenia, thrombocytopenia, band neutrophilia[3]	Findings are non-specific for FIP
	Serum biochemistry	Hyperglobulinemia, hypoalbuminemia, hyperbilirubinemia, low A:G ratio[3] Other abnormalities depending on organ involvement	A:G ratio: <0.4 = FIP slightly more likely >0.6 = FIP slightly less likely[78,123]
	AGP	Moderate to marked elevation[124]	>1.5 g/l = FIP moderately more likely >3.0 g/l = FIP highly more likely <1.5 g/l = FIP slightly less likely
Effusion	Rivalta's test	Positive	If negative, FIP highly unlikely[132]
	Cell count and cytology	Low to moderate cellularity, pyogranulomatous inflammation[137]	Important to rule out differential diagnoses such as neoplasia or septic effusion
	Bacterial culture	Negative	Important to rule out septic effusion
	Biochemical analysis (protein, A:G ratio)	High protein concentration Low A:G ratio[171]	A:G ratio: <0.4 = FIP moderately more likely >0.8 = FIP slightly less likely
	AGP	Moderate to marked elevation	>1.5 g/l = FIP moderately more likely[129]
Cerebrospinal fluid	Cell count and cytology	Moderate to marked pleocytosis Neutrophilic, mononuclear, mixed or pyogranulomatous inflammation[95,172]	Potentially helpful to rule out differential diagnoses in cats with neurological signs, but non-specific for FIP. CSF analysis can be unremarkable in some cats with FIP[105]
	Protein concentration	Moderate to marked elevation	Potentially helpful to rule out differential diagnoses in cats with neurological signs, but non-specific for FIP. CSF analysis can be unremarkable in some cats with FIP[105]
Aqueous humour	Cell count and cytology[173–175]	Neutrophilic, pyogranulomatous or mixed inflammation	Potentially helpful to rule out neoplasia, but often non-specific
Other	Routine diagnostic imaging (radiography or ultrasonography)	Ascites, pleural or pericardial effusion Abdominal lymphadenopathy Structural changes to liver, spleen, kidneys or intestines Evidence of peritonitis[82]	Highly useful to locate any effusion Ultrasound-guided sample collection (fine-needle aspiration,TCB) possible
	Advanced diagnostic imaging (CT or MRI)	Obstructive hydrocephalus, syringomyelia, foramen magnum herniation or marked meningeal or ependymal contrast enhancement indicating T3–L3 myelopathy, central vestibular syndrome or multifocal CNS disease[166]	Helpful in cats with neurological signs Can be unremarkable in some cats with FIP

*Modified from the European Advisory Board on Cat Diseases (ABCD) 'FIP diagnosis tool'[28] and Felten and Hartmann (2019)[80]
This table is available to download from the supplementary material (supplemental file 15a)

Table 5 Methods for direct and indirect detection of FCoV for diagnosis of FIP – an overview*

	Test	Sensitivity	Specificity	Comments
Blood	RT-PCR (including real-time RT-PCR and RT-nPCR)[58,78,79,122,153,176]	9–77%	88–100%	Not specific for FIP; FCoV viremia can also be detected in cats without FIP Usually very low viral load in cats with FIP[177]
	Real-time RT-PCR for *M* gene[144,170,178,179]	46–100%	48–100%	Not specific for FIP; FCoV mRNA can also be detected in cats without FIP
	S gene RT-PCR[58,122,154]	0–23%	95%	Can give false-positive results; not useful to confirm a diagnosis of FIP[154] Usually very low viral load in cats with FIP[177]
	Sequencing for *S* gene mutations[79,153]	7–43%	Not available	More useful than *S* gene RT-PCR Controversial whether *S* gene mutations are specific for FIP or only a marker for systemic spread of FCoV
	Antibody detection including *7b* ELISA[78,84,180]	28–85%	25–92%	Not specific for FIP; anti-FCoV antibodies can also be detected in cats without FIP
Effusion	Detection of FCoV antigen by IFA or ICC[78,130,165]	57–100%	71–100%	If positive in combination with consistent routine diagnostic tests – FIP very likely False-positive results possible in cats without FIP
	RT-PCR (including real-time RT-PCR and RT-nPCR)[58,60,67,78,79,153,169,176,181]	72–100%	83–100%	Not specific for FIP; FCoV RNA can also be detected in cats without FIP
	S gene RT-PCR[58,122,154]	64–69%	86–96%	Can give false-positive results; not useful to confirm a diagnosis of FIP[154]
	Sequencing for *S* gene mutations[79,153,181]	40–65%	83–98%	More useful than *S* gene RT-PCR Controversial whether *S* gene mutations are specific for FIP or only a marker for systemic spread of FCoV
	Antibody detection[78]	86%	85%	Not specific for FIP; anti-FCoV antibodies can also be detected in cats without FIP
Cerebrospinal fluid	Detection of FCoV antigen by ICC[163]	78–91%	50–88%	If positive in combination with consistent routine diagnostic tests – FIP very likely False-positive results possible in cats without FIP
	RT-PCR (including real-time RT-PCR and RT-nPCR)[58,60,105,106,150]	17–86%	100%	Not specific for FIP; FCoV RNA can also be detected in cats without FIP Sensitivity better in cats with neurological signs than in those without
	S gene RT-PCR[136,156,160]	8–44%	95%	Can give false-positive results; not useful to confirm a diagnosis of FIP[154]
	Antibody detection[105,173]	0–94%	93–100%	Not specific for FIP; anti-FCoV antibodies can also be detected in cats without FIP Sensitivity better in cats with neurological signs than in those without
Aqueous humour	Detection of FCoV antigen by ICC[175]	64%	82%	If positive in combination with consistent routine diagnostic tests – FIP very likely False-positive results possible in cats without FIP
	RT-PCR (including real-time RT-PCR and RT-nPCR)[58,60,151]	25–50%	100%	Not specific for FIP; FCoV RNA can also be detected in cats without FIP
	S gene RT-PCR[58,151,154]	10–13%	100%	Can give false-positive results; not useful to confirm a diagnosis of FIP[154]
Tissue	Detection of FCoV antigen by IHC	98%[156]	100%[156]	Gold standard for the diagnosis of FIP
	Detection of FCoV antigen by ICC in FNA specimens[139,141]	17–31% (liver) 11–20% (kidney) 53% (MLNs)	91% (MLNs)	If positive in combination with consistent routine diagnostic tests – FIP very likely False-positive results possible in cats without FIP
	RT-PCR (including real-time RT-PCR and RT-nPCR; FNA or biopsy specimens)[58,60,79,140,152,182]	65–100%	50–96%	Not specific for FIP; FCoV RNA can also be detected in cats without FIP Sensitivity depends on organ involvement
	S gene RT-PCR[58,152,154]	15–71%	67–100%	Can give false-positive results; not useful to confirm a diagnosis of FIP[154]
	Sequencing for *S* gene mutations[60,79,154,182]	70–89%	88–100%	More useful than *S* gene RT-PCR Controversial whether *S* gene mutations are specific for FIP or only a marker for systemic spread of FCoV

*Modified from Felten and Hartmann (2019)[80]
This table is available to download from the supplementary material (supplemental file 15b)

Summary of diagnostic testing for FIP

The difficulty when trying to diagnose FIP is that both indirect and direct detection methods only indicate the presence of FCoV and not specifically the mutated virus that leads to FIP. FCoV is present in many cats and even detection outside of the intestinal tract in effusions, tissues, CNS or aqueous humour is not diagnostic for FIP, as harmless non-mutated FCoV can be found everywhere in the body.[148,169,170] Detection of mutated FCoV (viruses containing certain *S* gene mutations) does not entirely solve the problem as viruses containing these mutations have been found in the tissues or fluids of cats without FIP.[60,61,79,80,154]

Probably the best approach for a relatively confident dagnosis is to find high quantities of FCoV RNA in the body, as it is well known that cats with FIP exhibit much higher viral loads than healthy FCoV-infected cats. Thus, a positive RT-qPCR result with a high viral load, if accompanied by consistent clinical signs and clinical pathology results, is at least very suggestive of FIP.[60,61,154]

If the history and presenting signs are consistent with FIP, and FCoV RNA is detected in fluid or tissue using real-time RT-PCR, then there is a high chance that the cat has FIP.



Definitively diagnosing FIP remains a challenge. The only way to truly confirm FIP is to detect the viral antigen associated with macrophages within lesions using IHC.[80,136] However, if the cat's history and presenting clinical signs are consistent with FIP and the FCoV RNA is detected in fluid or tissue using real-time RT-PCR, then there is a significant chance that the cat has FIP.[80] Ultimately, the diagnostic approach to diagnosing FIP must be tailored to the specific presentation of the individual cat. Tables 4 and 5 (provided as supplemental files 15a and 15b) contain pertinent diagnostic test findings that may significantly increase the index of suspicion that FIP is the underlying cause of a cat's clinical signs. Further, algorithms adapted for the different presentations of FIP have been provided by expert groups (see supplemental file 16) to help guide practitioners when working up a case.

KEY POINTS

- FCoV infection, usually asymptomatic, is common in most cat populations because the virus is highly contagious and spreads efficiently via fecal-oral transmission, leading to high prevalence in multi-cat environments, such as breeding catteries, shelters, rescue facilities and animal hoarding situations.
- A diagnosis of FIP can be challenging due to a lack of pathognomonic clinical signs and laboratory changes, especially when no effusion is present. There is no one non-invasive confirmatory test available for cats ante-mortem without effusion. Likewise, no diagnostic procedure is available to predict which FCoV-infected cats will eventually develop FIP.
- Cats with FIP typically have non-specific clinical signs such as anorexia, lethargy, a waxing/waning fever (often non-responsive to antibiotics), jaundice, lymphadenopathy and weight loss or, in kittens, failure to gain weight. More specific clinical signs include presence of effusion, anterior uveitis or neurological signs.
- Several risk factors (host, viral and environmental) have been identified for the development of FIP, including a recent stressful event noted as part of the cat's history.
- The clinician must consider the individual patient's history, signalment and comprehensive physical examination findings when selecting diagnostic tests and sample types in order to build the index of suspicion 'brick by brick'.
- Repeat examinations, including looking for pockets of effusions for cytological analysis, are often necessary in a difficult-to-diagnose case. If the cat presents with effusion, diagnosing FIP can be straightforward as tests using effusion generally have much higher predictive values than those using blood. The Rivalta's test is one such example of an easy, rapid and inexpensive test on an effusion sample that has good sensitivity for excluding FIP (91–100%). If the Rivalta's test is negative, other potential causes for the effusion are much more likely than FIP.
- If no effusion is present, diagnosis can become quite challenging due to the variety and non-specificity of possible clinical signs. A good understanding of each diagnostic test's sensitivity, specificity, predictive value, likelihood ratio and diagnostic accuracy is important when building a case for FIP. Before proceeding with any diagnostic test or commercial laboratory profile, the clinician should be able to answer the questions of 'why this test?' and 'what do the results mean?'
- When considering PCR testing, it is important to bear in mind that one RT-PCR may not be identical to another (eg, in terms of FCoV target sequence). Prior to submitting a sample, it is recommended the clinician contacts the laboratory for information regarding what that particular assay is targeting, to help guide sample selection for submission.
- Unlike many other feline diseases, blood samples are generally not helpful in the diagnosis of FIP.
- The only way to truly confirm FIP is to detect the virus (either by antigen staining or RT-PCR) within tissue and this requires taking histopathology samples. FCoV antigen detection in macrophages of affected tissues via immunostaining is considered the gold standard for diagnosing FIP.
- Ultimately, the approach to diagnosing FIP must be tailored to the specific presentation of the individual cat.



Supplementary material

The following files are available online at jfms.com and can be accessed at catvets.com/fip and everycat.org/aafp-fip-guidelines:

- Supplemental figure 1: FCoV genome.
- Supplemental figure 2: Origin of FCoV serotype II.
- Supplemental figure 3: Fecal-oral transmission of FCoV.
- Supplemental figure 4: (a–d) Pathogenesis pathway from less-virulent FCoV infection to FIP-associated FCoV.
- Supplemental file 5a: Pathogenesis of FIP.
- Supplemental file 5b: Macrophage activation, complement activation and antibody-mediated viral infection of macrophages.
- Supplemental figure 6: Host immune response to FCoV infection.
- Supplemental file 7: Purebred cat breeds with FIP representation in two studies.
- Supplemental figure 8: Diagnostic work-up for FIP 'brick by brick'.
- Supplemental file 9: Health-related history questionnaire.
- Supplemental video 10: Progressive neurological FIP in the cat shown in Figure 5.
- Supplemental video 11: Abdominal effusion due to FIP in the cat shown in Figure 12.
- Supplemental file 12: A complicated differential diagnostic case in a cat suspected of having FIP.
- Supplemental video 13: Rivalta's test being performed.
- Supplemental file 14: Instructions for TFAST and AFAST.
- Supplemental file 15a: Routine diagnostic testing for FIP – an overview.
- Supplemental file 15b: Methods for direct and indirect detection of FCoV for diagnosis of FIP – an overview.
- Supplemental file 16: Diagnostic work-up of FIP: diagnostic approach.

Acknowledgements

The Task Force gratefully acknowledges the contribution of Dr Gregory Lisciandro, Dr Sally Lester, Dr Brian Geiss, Daniel Dominguez and Heather O'Steen in the preparation of the guidelines manuscript. Figure 1 was produced by graphic artist Rachael Weiss. Supplemental file 16 is included with kind permission of the European Advisory Board on Cat Diseases (ABCD).

Conflict of interest

The Task Force members have no conflicts of interest to declare.

Funding

These Guidelines were supported by an educational grant from Boehringer Ingelheim Animal Health USA Inc. The members of the Task Force received no financial support for the research, authorship, and/or publication of this article.

Ethical approval

This work did not involve the use of animals and therefore ethical approval was not specifically required for publication in *JFMS*.

Informed consent

This work did not involve the use of animals (including cadavers) and therefore informed consent was not required. For any animals or people individually identifiable within this publication, informed consent (verbal or written) for their use in the publication was obtained from the people involved.

GLOSSARY

Feline coronavirus (FCoV) Feline infectious peritonitis (FIP) is caused by a feline coronavirus (FCoV). FCoVs are enveloped, positive-stranded RNA viruses characterized by club-like spikes that project from their surface and have unusually large viral RNA genomes. FCoV belongs to the α-coronavirus genus.

Bio- or pathotypes FCoVs are designated to two biotypes (pathotypes), each having different target host cells and different potentials for disease. However, because all FCoVs can be found and replicate systemically, current literature more commonly refers to both biotypes as FCoV.
– **Feline enteric coronavirus (FECV)** is a term often used interchangeably with FCoV. FECV mainly replicates in the enteric epithelium yet can also infect monocytes and spread systemically by monocyte viremia. FECV is now often called the 'less-virulent', non-mutated biotype form of FCoV.
– **Feline infectious peritonitis virus (FIPV)** is currently referred to as the FIP-associated or mutated virulent biotype form of FCoV. FIPV causes a highly fatal disease due to internal mutations of FECV resulting in a change of tropism from enterocytes to an affinity for monocytes/macrophages.
– Both bio- or pathotypes (FECV and FIPV) exist as two serotypes (type I and type II).

Serotypes FCoV has two serotypes, I and II (defined by a historical recombination event in the spike [*S*] gene between feline and canine coronavirus). Both serotypes can cause FIP.
– **Serotype I** has a distinctly felid spike protein and does not grow well in cell culture. This serotype may be more likely to cause clinical FIP and makes up over 90% of FECV isolates in North America and Europe. The cellular receptor for serotype I is unknown.
– **Serotype II** FCoVs are a cross-species recombination between the *S* gene region of type I FCoVs and canine coronavirus, and are more adaptable to cell culture.
This serotype makes up 20% or more of the FECV isolates in Asian countries. Serotype II uses the feline aminopeptidase-N receptor on the intestinal villi for cell entry.

Quasispecies: RNA viruses have high error rates in their replication and therefore occur as quasispecies (eg, groups of related genotypes).

Tropism The capability of a virus to infect a distinct group of cells in the host is referred to as tropism. For many viruses, tropism is determined by the availability of virus receptors on the surface of a host cell. In the pathogenesis of FIP, a spontaneous mutation will occur in individual cats, leading to a change in cell tropism from enterocytes to monocytes/ macrophages.

Prevalence The proportion of individuals in a population having a disease or characteristic. Prevalence is a statistical concept referring to the number of cases of a disease that are present in a particular population at a given time.

References

1 Holzworth J. **Some important disorders of cats.** *Cornell Vet* 1963; 53: 157–160.

2 Klein-Richers U, Hartmann K, Hofmann-Lehmann R, et al. **Prevalence of feline coronavirus shedding in German catteries and associated risk factors.** *Viruses* 2020; 12: 1000–1013.

3 Riemer F, Kuehner KA, Ritz S, et al. **Clinical and laboratory features of cats with feline infectious peritonitis – a retrospective study of 231 confirmed cases (2000–2010).** *J Feline Med Surg* 2016; 18: 348–356.

4 Pesteanu-Somogyi LD, Radzai C and Pressler BM. **Prevalence of feline infectious peritonitis in specific cat breeds.** *J Feline Med Surg* 2006; 8: 1–5.

5 Rohrbach BW, Legendre AM, Baldwin CA, et al. **Epidemiology of feline infectious peritonitis among cats examined at veterinary medical teaching hospitals.** *J Am Vet Med Assoc* 2001; 218: 1111–1115.

6 Masters P and Perlman S. **Coronaviridae.** In: Knipe D and Howley P (eds). Fields virology. Philadelphia: Lippincott Williams & Wilkins, 2013, pp 825–858.

7 Paltrinieri S, Giordano A, Stranieri A, et al. **Feline infectious peritonitis (FIP) and coronavirus disease 19 (COVID-19): are they similar?** *Transbound Emerg Dis* 2021; 68: 1786–1799.

8 Stout AE, André NM, Jaimes JA, et al. **Coronaviruses in cats and other companion animals: where does SARS-CoV-2/COVID-19 fit?** *Vet Microbiol* 2020; 247. DOI: 10.1016/j.vetmic.2020.108777.

9 Pedersen NC, Allen CE and Lyons LA. **Pathogenesis of feline enteric coronavirus infection.** *J Feline Med Surg* 2008; 10: 529–541.

10 Pedersen NC, Liu H, Scarlett J, et al. **Feline infectious peritonitis: role of the feline coronavirus 3c gene in intestinal tropism and pathogenicity based upon isolates from resident and adopted shelter cats.** *Virus Res* 2012; 165: 17–28.

11 Pedersen NC, Black JW, Boyle JF, et al. **Pathogenic differences between various feline coronavirus isolates.** *Adv Exp Med Biol* 1984; 173: 365–380.

12 Herrewegh AAPM, Smeenk I, Horzinek MC, et al. **Feline coronavirus type II strains 79-1683 and 79-1146 originate from a double recombination between feline coronavirus type I and canine coronavirus.** *J Virol* 1998; 72: 4508–4514.

13 Terada Y, Matsui N, Noguchi K, et al. **Emergence of pathogenic coronaviruses in cats by homologous recombination between feline and canine coronaviruses.** *PLoS One* 2014; 9. DOI: 10.1371/journal.pone.0106534.

14 Benetka V, Kübber-Heiss A, Kolodziejek J, et al. **Prevalence of feline coronavirus types I and II in cats with histopathologically verified feline infectious peritonitis.** *Vet Microbiol* 2004; 99: 31–42.

15 Kummrow M, Meli ML, Haessig M, et al. **Feline coronavirus serotypes 1 and 2: seroprevalence and association with disease in Switzerland.** *Clin Diagn Lab Immunol* 2005; 12: 1209–1215.

16 Wesseling JG, Vennema H, Godeke GJ, et al. **Nucleotide sequence and expression of the spike (S) gene of canine coronavirus and comparison with the S proteins of feline and porcine coronaviruses.** *J Gen Virol* 1994; 75: 1789–1794.

17 Pedersen NC. **An update on feline infectious peritonitis: virology and immunopathogenesis.** *Vet J* 2014; 201: 123–132.

18 Lin CN, Chang RY, Su BL, et al. **Full genome analysis of a novel type II feline coronavirus NTU156.** *Virus Genes* 2013; 46: 316–322.

19 Tusell SM, Schittone SA and Holmes KV. **Mutational analysis of aminopeptidase N, a receptor for several group 1 coronaviruses, identifies key determinants of viral host range.** *J Virol* 2007; 81: 1261–1273.

20 Tekes G, Hofmann-Lehmann R, Bank-Wolf B, et al. **Chimeric feline coronaviruses that encode type II spike protein on type I genetic background display accelerated viral growth and altered receptor usage.** *J Virol* 2010; 84: 1326–1333.

21 Dye C and Siddell SG. **Genomic RNA sequence of feline coronavirus strain FCoV C1Je.** *J Feline Med Surg* 2007; 9: 202–213.

22 Poland AM, Vennema H, Foley JE, et al. **Two related strains of feline infectious peritonitis virus isolated from immunocompromised cats infected with a feline enteric coronavirus.** *J Clin Microbiol* 1996; 34: 3180–3184.

23 Vennema H, Poland A, Foley J, et al. **Feline infectious peritonitis viruses arise by mutation from endemic feline enteric coronaviruses.** *Virology* 1998; 243: 150–157.

24 Pedersen NC, Liu H, Dodd KA, et al. **Significance of coronavirus mutants in feces and diseased tissues of cats suffering from feline infectious peritonitis.** *Viruses* 2009; 1: 166–184.

25 Chang HW, Egberink HF, Halpin R, et al. **Spike protein fusion peptide and feline coronavirus virulence.** *Emerg Infect Dis* 2012; 18: 1089–1095.

26 Rottier PJM, Nakamura K, Schellen P, et al. **Acquisition of macrophage tropism during the pathogenesis of feline infectious peritonitis is determined by mutations in the feline coronavirus spike protein.** *J Virol* 2005; 79: 14122–14130.

27 Horzinek MC and Osterhaus AD. **Feline infectious peritonitis: a worldwide serosurvey.** *Am J Vet Res* 1979; 40: 1487–1492.

28 ABCD. **Feline infectious peritonitis. General guidelines from the European Advisory Board on Cat Diseases.** abcdcatsvets.org/feline-infectious-peritonitis (March 2021, accessed 6 April, 2022).

29 Foley JE, Poland A, Carlson J, et al. **Risk factors for feline infectious peritonitis among cats in multiple-cat environments with endemic feline enteric coronavirus.** *J Am Vet Med Assoc* 1997; 210: 1313–1318.

30 Herrewegh AAPM, Mähler M, Hedrich HJ, et al. **Persistence and evolution of feline coronavirus in a closed cat-breeding colony.** *Virology* 1997; 234: 349–363.

31 Addie DD. **Clustering of feline coronaviruses in multicat households.** *Vet J* 2000; 159: 8–9.

32 Addie DD and Jarrett O. **Use of a reverse-transcriptase polymerase chain reaction for monitoring the shedding of feline coronavirus by healthy cats.** *Vet Rec* 2001; 148: 649–653.

33 Cave TA, Golder MC, Simpson J, et al. **Risk factors for feline coronavirus seropositivity in cats relinquished to a UK rescue charity.** *J Feline Med Surg* 2004; 6: 53–58.

34 Holst BS, Englund L, Palacios S, et al. **Prevalence of antibodies against feline coronavirus and *Chlamydophila felis* in Swedish cats.** *J Feline Med Surg* 2006; 8: 207–211.

35 Sharif S, Arshad SS, Hair-Bejo M, et al. **Prevalence of feline coronavirus in two cat populations in Malaysia.** *J Feline Med Surg* 2009; 11: 1031–1034.

36 Pedersen NC, Sato R, Foley JE, et al. **Common virus infections in cats, before and after being placed in shelters, with emphasis on feline enteric coronavirus.** *J Feline Med Surg* 2004; 6: 83–88.

37 Pedersen NC, Boyle JF, Floyd K, et al. **An enteric coronavirus infection of cats and its relationship to feline infectious peritonitis.** *Am J Vet Res* 1981; 42: 368–377.

38 Kipar A, Meli ML, Baptiste KE, et al. **Sites of feline coronavirus persistence in healthy cats.** *J Gen Virol* 2010; 91: 1698–1707.

39 Vogel L, Van Der Lubben M, Te Lintelo EG, et al. **Pathogenic characteristics of persistent feline enteric coronavirus infection in cats.** *Vet Res* 2010; 41: 71. DOI: 10.1051/vetres/2010043.

40 Addie DD, Paltrinieri S and Pedersen NC. **Recommendations from workshops of the second international feline coronavirus/feline infectious peritonitis symposium.** *J Feline Med Surg* 2004; 6: 125–130.

41 Foley JE, Poland A, Carlson J, et al. **Patterns of feline coronavirus infection and fecal shedding from cats in multiple-cat environments.** *J Am Vet Med Assoc* 1997; 210: 1307–1312.

42 Addie DD, Schaap IAT, Nicolson L, et al. **Persistence and transmission of natural type I feline coronavirus infection.** *J Gen Virol* 2003; 84: 2735–2744.

43 Harpold LM, Legendre AM, Kennedy MA, et al. **Fecal shedding of feline coronavirus in adult cats and kittens in an Abyssinian cattery.** *J Am Vet Med Assoc* 1999; 215: 948–951.

44 Lutz H, Gut M, Leutenegger CM, et al. **Kinetics of FCoV infection in kittens born in catteries of high risk for FIP under different rearing conditions.** Proceedings of the Second International Feline Coronavirus/Feline Infectious Peritonitis Symposium. 2002 August 4–7; Glasgow, Scotland.

45 Drechsler Y, Alcaraz A, Bossong FJ, et al. **Feline coronavirus in multicat environments.** *Vet Clin North Am Small Anim Pract* 2011; 41: 1133–1169.

46 Felten S, Klein-Richers U, Hofmann-Lehmann R, et al. **Correlation of feline coronavirus shedding in feces with coronavirus antibody titer.** *Pathogens* 2020; 9: 598. DOI: 10.3390/pathogens9080598.

47 Dye C, Helps CR and Siddell SG. **Evaluation of real-time RT-PCR for the quantification of FCoV shedding in the faeces of domestic cats.** *J Feline Med Surg* 2008; 10: 167–174.

48 Hartmann K. **Feline infectious peritonitis.** *Vet Clin North Am Small Anim Pract* 2005; 35: 39–79.

49 Addie D. **Feline coronavirus infections.** In: Greene C (ed). Infectious diseases of the dog and cat. St Louis, MO: Elsevier, 2012, pp 92–108.

50 Pedersen NC. **An update on feline infectious peritonitis: diagnostics and therapeutics.** *Vet J* 2014; 201: 133–141.

51 Sabshin SJ, Levy JK, Tupler T, et al. **Enteropathogens identified in cats entering a Florida animal shelter with normal feces or diarrhea.** *J Am Vet Med Assoc* 2012; 241: 331–337.

52 Olsen CW, Corapi WV, Ngichabe CK, et al. **Monoclonal antibodies to the spike protein of feline infectious peritonitis virus mediate antibody-dependent enhancement of infection of feline macrophages.** *J Virol* 1992; 66: 956–965.

53 Yang TJ, Chang YC, Ko TP, et al. **Cryo-EM analysis of a feline coronavirus spike protein reveals a unique structure and camouflaging glycans.** *Proc Natl Acad Sci USA* 2020; 117: 1438–1446.

54 Dewerchin HL, Cornelissen E and Nauwynck HJ. **Replication of feline coronaviruses in peripheral blood monocytes.** *Arch Virol* 2005; 150: 2483–2500.

55 Malbon AJ, Michalopoulou E, Meli ML, et al. **Colony stimulating factors in early feline infectious peritonitis virus infection of monocytes and in end stage feline infectious peritonitis; a combined in vivo and in vitro approach.** *Pathogens* 2020; 9: 893. DOI: 10.3390/pathogens9110893.

56 Licitra BN, Millet JK, Regan AD, et al. **Mutation in spike protein cleavage site and pathogenesis of feline coronavirus.** *Emerg Infect Dis* 2013; 19: 1066–1073.

57 Barker EN, Tasker S, Gruffydd-Jones TJ, et al. **Phylogenetic analysis of feline coronavirus strains in an epizootic outbreak of feline infectious peritonitis.** *J Vet Intern Med* 2013; 27: 445–450.

58 Emmler L, Felten S, Matiasek K, et al. **Feline coronavirus with and without spike gene mutations detected by real-time RT-PCRs in cats with feline infectious peritonitis.** *J Feline Med Surg* 2020; 22: 791–799.

59 Decaro N, Mari V, Lanave G, et al. **Mutation analysis of the spike protein in Italian feline infectious peritonitis virus and feline enteric coronavirus sequences.** *Res Vet Sci* 2021; 135: 15–19. DOI: 10.1016/j.rvsc.2020.12.023.

60 Barker EN, Stranieri A, Helps CR, et al. **Limitations of using feline coronavirus spike protein gene mutations to diagnose feline infectious peritonitis.** *Vet Res* 2017; 48: 60. DOI: 10.1186/s13567-017-0467-9.

61 Porter E, Tasker S, Day MJ, et al. **Amino acid changes in the spike protein of feline coronavirus correlate with systemic spread of virus from the intestine and not with feline infectious peritonitis.** *Vet Res* 2014; 45: 49–59.

62 Wang Y-T, Hsieh L-E, Dai Y-R, et al. **Polymorphisms in the feline TNFA and CD209 genes are associated with the outcome of feline coronavirus infection.** *Vet Res* 2014; 45: 123. DOI: 10.1186/s13567-014-0123-6.

63 Kass PH and Dent TH. **The epidemiology of feline infectious peritonitis in catteries.** *Feline Pract* 1995; 23: 27–32.

64 Mustaffa-Kamal F, Liu H, Pedersen NC, et al. **Characterization of antiviral T cell responses during primary and secondary challenge of laboratory cats with feline infectious peritonitis virus (FIPV).** *BMC Vet Res* 2019; 15: 165. DOI: 10.1186/s12917-019-1909-6.

65 Kipar A, Meli ML, Failing K, et al. **Natural feline coronavirus infection: differences in cytokine patterns in association with the outcome of infection.** *Vet Immunol Immunopathol* 2006; 112: 141–155.

66 Norris JM, Bosward KL, White JD, et al. **Clinicopathological findings associated with feline infectious peritonitis in Sydney, Australia: 42 cases (1990–2002).** *Aust Vet J* 2005; 83: 666–673.

67 Tsai HY, Chueh LL, Lin CN, et al. **Clinicopathological findings and disease staging of feline infectious peritonitis: 51 cases from 2003 to 2009 in Taiwan.** *J Feline Med Surg* 2011; 13: 74–80.

68 Worthing KA, Wigney DI, Dhand NK, et al. **Risk factors for feline infectious peritonitis in Australian cats.** *J Feline Med Surg* 2012; 14: 405–412.

69 Soma T, Wada M, Taharaguchi S, et al. **Detection of ascitic feline coronavirus RNA from cats with clinically suspected feline infectious peritonitis.** *J Vet Med Sci* 2013; 75: 1389–1392.

70 Fischer Y, Wess G and Hartmann K. **Pericardial effusion in a cat with feline infectious peritonitis.** *Schweiz Arch Tierheilkd* 2012; 154: 27–31.

71 Savary KCM, Sellon RK and Law JMH. **Chylous abdominal effusion in a cat with feline infectious peritonitis.** *J Am Anim Hosp Assoc* 2001; 37: 35–40.

72 Cotter SM, Gilmore CE and Rollins C. **Multiple cases of feline leukemia and feline infectious peritonitis in a household.** *J Am Vet Med Assoc* 1973; 162: 1054–1058.

73 Kennedy MA. **Feline infectious peritonitis: update on pathogenesis, diagnostics, and treatment.** *Vet Clin North Am Small Anim Pract* 2020; 50: 1001–1011.

74 Hurley K. **Feline infectious peritonitis/feline enteric coronavirus (FIP/FECV).** https://www.sheltermedicine.com/library/resources/?r=feline-infectious-peritonitis-feline-coronavirus-fip-fcov (2020, accessed 3 June, 2022).

75 Tasker S and Dowgray N. **Managing feline coronavirus and feline infectious peritonitis in the multi-cat/shelter environment.** In: Dean R, Roberts M and Stavisky J (eds). BSAVA manual of canine and feline shelter medicine: principles of health and welfare in a multi-animal environment. Gloucester: BSAVA Publications, 2018, pp 256–267.

76 Hickman MA, Morris JG, Rogers QR, et al. **Elimination of feline coronavirus infection from a large experimental specific**

pathogen-free cat breeding colony by serologic testing and isolation. *Feline Pract* 1995; 23: 96–102.
77 Wang YT, Su BL, Hsieh LE, et al. **An outbreak of feline infectious peritonitis in a Taiwanese shelter: epidemiologic and molecular evidence for horizontal transmission of a novel type II feline coronavirus.** *Vet Res* 2013; 44: 57. DOI: 10.1186/1297-9716-44-57.
78 Hartmann K, Binder C, Hirschberger J, et al. **Comparison of different tests to diagnose feline infectious peritonitis.** *J Vet Intern Med* 2003; 17: 781–790.
79 Stranieri A, Giordano A, Paltrinieri S, et al. **Comparison of the performance of laboratory tests in the diagnosis of feline infectious peritonitis.** *J Vet Diagn Invest* 2018; 30: 459–463.
80 Felten S and Hartmann K. **Diagnosis of feline infectious peritonitis: a review of the current literature.** *Viruses* 2019; 11: 1068. DOI: 10.3390/v11111068.
81 Hartmann K. **Coronavirus infections (canine and feline), including feline infectious peritonitis.** In: Ettinger SJ, Feldman EC and Coté E (eds). Textbook of veterinary internal medicine. St Louis, MO: Elsevier, 2018, pp 983–991.
82 Lewis KM and O'Brien RT. **Abdominal ultrasonographic findings associated with feline infectious peritonitis: a retrospective review of 16 cases.** *J Am Anim Hosp Assoc* 2010; 46: 152–160.
83 Sparkes AH, Gruffydd-Jones T and Harbour DA. **An appraisal of the value of laboratory tests in the diagnosis of feline infectious peritonitis.** *J Am Anim Hosp Assoc* 1994; 30: 345–350.
84 Sparkes AH, Gruffydd-Jones TJ and Harbour DA. **Feline infectious peritonitis: a review of clinicopathological changes in 65 cases, and a critical assessment of their diagnostic value.** *Vet Rec* 1991; 129: 345–350.
85 Tasker S. **Diagnosis of feline infectious peritonitis: update on evidence supporting available tests.** *J Feline Med Surg* 2018; 20: 228–243.
86 Pedersen NC. **A review of feline infectious peritonitis virus infection: 1963–2008.** *J Feline Med Surg* 2009; 11: 225–258.
87 Pedersen NC. **Feline infectious peritonitis: something old, something new.** *Feline Pract* 1976; 6: 42–51.
88 Kipar A and Meli ML. **Feline infectious peritonitis: still an enigma?** *Vet Pathol* 2014; 51: 505–526.
89 Addie DD, Kennedy LJ, Ryvar R, et al. **Feline leucocyte antigen class II polymorphism and susceptibility to feline infectious peritonitis.** *J Feline Med Surg* 2004; 6: 59–62.
90 Addie DD, Toth S, Murray GD, et al. **The risk of typical and antibody enhanced feline infectious peritonitis among cats from feline coronavirus endemic households.** *Feline Pract* 1995; 23: 24–26.
91 Addie DD, Toth S, Murray GD, et al. **Risk of feline infectious peritonitis in cats naturally infected with feline coronavirus.** *Am J Vet Res* 1995; 56: 429–434.
92 Yin Y, Li T, Wang C, et al. **A retrospective study of clinical and laboratory features and treatment on cats highly suspected of feline infectious peritonitis in Wuhan, China.** *Sci Rep* 2021; 11. DOI: 10.1038/s41598-021-84754-0.
93 Foley JE and Pedersen NC. **The inheritance of susceptibility to feline infectious peritonitis in purebred catteries.** *Feline Pract* 1996; 24: 14–22.
94 Giori L, Giordano A, Giudice C, et al. **Performances of different diagnostic tests for feline infectious peritonitis in challenging clinical cases.** *J Small Anim Pract* 2011; 52: 152–157.
95 Crawford AH, Stoll AL, Sanchez-Masian D, et al. **Clinicopathologic features and magnetic resonance imaging findings in 24 cats with histopathologically confirmed neurologic feline infectious peritonitis.** *J Vet Intern Med* 2017; 31: 1477–1486.
96 Hirschberger J, Hartmann K, Wilhelm N, et al. **Clinical symptoms and diagnosis of feline infectious peritonitis.** *Tierärztliche Prax* 1995; 23: 92–99.
97 König A, Hartmann K, Mueller RS, et al. **Retrospective analysis of pleural effusion in cats.** *J Feline Med Surg* 2019; 21: 1102–1110.
98 Ruiz MD, Vessières F, Ragetly GR, et al. **Characterization of and factors associated with causes of pleural effusion in cats.** *J Am Vet Med Assoc* 2018; 253: 181–187.
99 Künzel F, Rebel-Bauder B, Kassl C, et al. **Meningoencephalitis in cats in Austria: a study of infectious causes, including *Encephalitozoon cuniculi*.** *J Feline Med Surg* 2017; 19: 171–176.
100 Kipar A, Koehler K, Bellmann S, et al. **Feline infectious peritonitis presenting as a tumour in the abdominal cavity.** *Vet Rec* 1999; 144: 118–122.
101 Hugo TB and Heading KL. **Prolonged survival of a cat diagnosed with feline infectious peritonitis by immunohistochemistry.** *Can Vet J* 2015; 56: 53–58.
102 Harvey CJ, Lopez JW and Hendrick MJ. **An uncommon intestinal manifestation of feline infectious peritonitis: 26 cases (1986–1993).** *J Am Vet Med Assoc* 1996; 209: 1117–1120.
103 O'Halloran C and Gunn-Moore D. **Mycobacteria in cats: an update.** *In Pract* 2017; 39: 399–406.
104 Cohen TM, Blois S and Vince AR. **Fatal extraintestinal toxoplasmosis in a young male cat with enlarged mesenteric lymph nodes.** *Can Vet J* 2016; 57: 483–486.
105 Foley JE, Lapointe JM, Koblik P, et al. **Diagnostic features of clinical neurologic feline infectious peritonitis.** *J Vet Intern Med* 1998; 12: 415–423.
106 Doenges SJ, Weber K, Dorsch R, et al. **Detection of feline coronavirus in cerebrospinal fluid for diagnosis of feline infectious peritonitis in cats with and without neurological signs.** *J Feline Med Surg* 2016; 18: 104–109.
107 Diaz JV and Poma R. **Diagnosis and clinical signs of feline infectious peritonitis in the central nervous system.** *Can Vet J* 2009; 50: 1091–1093.
108 Mella SL, Cardy TJA, Volk HA, et al. **Clinical reasoning in feline spinal disease: which combination of clinical information is useful?** *J Feline Med Surg* 2020; 22: 521–530.
109 Maggs DJ. **Feline uveitis: an 'intraocular lymphadenopathy'.** *J Feline Med Surg* 2009; 11: 167–182.
110 Stiles J. **Ocular manifestations of feline viral diseases.** *Vet J* 2014; 201: 166–173.
111 Jinks MR, English RV and Gilger BC. **Causes of endogenous uveitis in cats presented to referral clinics in North Carolina.** *Vet Ophthalmol* 2016; 19: 30–37.
112 Wegg ML, Jeanes EC, Pollard D, et al. **A multicenter retrospective study into endogenous causes of uveitis in cats in the United Kingdom: ninety two cases.** *Vet Ophthalmol* 2021; 24: 591–598.
113 Cannon MJ, Silkstone MA and Kipar AM. **Cutaneous lesions associated with coronavirus-induced vasculitis in a cat with feline infectious peritonitis and concurrent feline immunodeficiency virus infection.** *J Feline Med Surg* 2005; 7: 233–236.
114 Declercq J, De Bosschere H, Schwarzkopf I, et al. **Papular cutaneous lesions in a cat associated with feline infectious peritonitis.** *Vet Dermatol* 2008; 19: 255–258.
115 Bauer BS, Kerr ME, Sandmeyer LS, et al. **Positive immunostaining for feline infectious peritonitis (FIP) in a Sphinx cat with cutaneous lesions and bilateral panuveitis.** *Vet Ophthalmol* 2013; 16: 160–163.
116 Redford T and Al-Dissi AN. **Feline infectious peritonitis in a cat presented because of papular skin lesions.** *Can Vet J* 2019; 60: 183–185.

117 Trotman TK, Mauldin E, Hoffmann V, et al. **Skin fragility syndrome in a cat with feline infectious peritonitis and hepatic lipidosis.** *Vet Dermatol* 2007; 18: 365–369.
118 Rota A, Paltrinieri S, Jussich S, et al. **Priapism in a castrated cat associated with feline infectious peritonitis.** *J Feline Med Surg* 2008; 10: 181–184.
119 Hartmann K, Pennisi MG and Dorsch R. **Infectious agents in feline chronic kidney disease.** *Adv Small Anim Care* 2020; 1: 189–206.
120 Baral RM. **Approach to the cat with ascites and diseases affecting the peritoneal cavity.** In: Little SE (ed). The cat: clinical medicine and management. Elsevier Saunders, 2012, pp 538–546.
121 Šimundić A-M. **Measures of diagnostic accuracy: basic definitions.** *EJIFCC* 2009; 19: 203–211.
122 Felten S, Leutenegger CM, Balzer HJ, et al. **Sensitivity and specificity of a real-time reverse transcriptase polymerase chain reaction detecting feline coronavirus mutations in effusion and serum/plasma of cats to diagnose feline infectious peritonitis.** *BMC Vet Res* 2017; 13: 228. DOI: 10.1186/s12917-017-1147-8.
123 Jeffery U, Deitz K and Hostetter S. **Positive predictive value of albumin:globulin ratio for feline infectious peritonitis in a midwestern referral hospital population.** *J Feline Med Surg* 2012; 14: 903–905.
124 Saverio P, Alessia G, Vito T, et al. **Critical assessment of the diagnostic value of feline α1-acid glycoprotein for feline infectious peritonitis using the likelihood ratios approach.** *J Vet Diagn Invest* 2007; 19: 266–272.
125 Valenciano AC and Rizzi TE. **Abdominal, thoracic, and pericardial effusions.** In: Valenciano AC and Cowell R (eds). Cowell and Tyler's diagnostic cytology and hematology of the dog and cat. St Louis, MO: Mosby, 2020, pp 229–246.
126 Dörfelt S, Matiasek LA, Felten S, et al. **Antigens under cover – the preservation and demasking of selected antigens for successful poststaining immunocytochemistry of effusion, brain smears, and lymph node aspirates.** *Vet Clin Pathol* 2019; 48 Suppl 1: 98–107.
127 Ritz S, Egberink H and Hartmann K. **Effect of feline interferon-omega on the survival time and quality of life of cats with feline infectious peritonitis.** *J Vet Intern Med* 2007; 21: 1193–1197.
128 Baek SY, Jo JG, Song KH, et al. **Recurrent pericardial effusion with feline infectious peritonitis in a cat.** *J Vet Clin* 2017; 34: 437–440.
129 Hazuchova K, Held S and Neiger R. **Usefulness of acute phase proteins in differentiating between feline infectious peritonitis and other diseases in cats with body cavity effusions.** *J Feline Med Surg* 2017; 19: 809–816.
130 Felten S, Matiasek K, Gruendl S, et al. **Investigation into the utility of an immunocytochemical assay in body cavity effusions for diagnosis of feline infectious peritonitis.** *J Feline Med Surg* 2017; 19: 410–418.
131 Fischer Y, Weber K, Sauter-Louis C, et al. **The Rivalta's test as a diagnostic variable in feline effusions – evaluation of optimum reaction and storage conditions.** *Tierarztl Prax Ausgabe K Kleintiere – Heimtiere* 2013; 41: 297–303.
132 Fischer Y, Sauter-Louis C and Hartmann K. **Diagnostic accuracy of the Rivalta test for feline infectious peritonitis.** *Vet Clin Pathol* 2012; 41: 558–567.
133 Paltrinieri S, Cammarata Parodi M and Cammarata G. **In vivo diagnosis of feline infectious peritonitis by comparison of protein content, cytology, and direct immunofluorescence test on peritoneal and pleural effusions.** *J Vet Diagn Invest* 1999: 11: 358–361.
134 Lisciandro G (ed). Point-of-care ultrasound techniques for the small animal practitioner. 2nd ed. Wiley-Blackwell, 2021.
135 Schreurs E, Vermote K, Barberet V, et al. **Ultrasonographic anatomy of abdominal lymph nodes in the normal cat.** *Vet Radiol Ultrasound* 2008; 49: 68–72.
136 Stranieri A, Scavone D, Paltrinieri S, et al. **Concordance between histology, immunohistochemistry, and RT-PCR in the diagnosis of feline infectious peritonitis.** *Pathogens* 2020; 9: 852. DOI: 0.3390/pathogens9100852.
137 Paltrinieri S, Cammarata Parodi M, Cammarata G, et al. **Type IV hypersensitivity in the pathogenesis of FIPV-induced lesions.** *Zentralbl Veterinarmed B* 1998; 45: 151–159.
138 Kipar A, May H, Menger S, et al. **Morphologic features and development of granulomatous vasculitis in feline infectious peritonitis.** *Vet Pathol* 2005; 42: 321–330.
139 Felten S, Hartmann K, Doerfelt S, et al. **Immunocytochemistry of mesenteric lymph node fine-needle aspirates in the diagnosis of feline infectious peritonitis.** *J Vet Diagn Invest* 2019; 31: 210–216.
140 Dunbar D, Kwok W, Graham E, et al. **Diagnosis of non-effusive feline infectious peritonitis by reverse transcriptase quantitative PCR from mesenteric lymph node fine-needle aspirates.** *J Feline Med Surg* 2019; 21: 910–921.
141 Giordano A, Paltrinieri S, Bertazzolo W, et al. **Sensitivity of Tru-cut and fine-needle aspiration biopsies of liver and kidney for diagnosis of feline infectious peritonitis.** *Vet Clin Pathol* 2005; 34: 368–374.
142 Liffman R and Courtman N. **Fine needle aspiration of abdominal organs: a review of current recommendations for achieving a diagnostic sample.** *J Small Anim Pract* 2017; 58: 599–609.
143 Chang HW, de Groot RJ, Egberink HF, et al. **Feline infectious peritonitis: insights into feline coronavirus pathobiogenesis and epidemiology based on genetic analysis of the viral 3c gene.** *J Gen Virol* 2010; 91: 415–420.
144 Simons FA, Vennema H, Rofina JE, et al. **A mRNA PCR for the diagnosis of feline infectious peritonitis.** *J Virol Methods* 2005; 124: 111–116.
145 Gamble DA, Lobbiani A, Gramegna M, et al. **Development of a nested PCR assay for detection of feline infectious peritonitis virus in clinical specimens.** *J Clin Microbiol* 1997; 35: 673–675.
146 Herrewegh AAPM, De Groot RJ, Cepica A, et al. **Detection of feline coronavirus RNA in feces, tissues, and body fluids of naturally infected cats by reverse transcriptase PCR.** *J Clin Microbiol* 1995; 33: 684–689.
147 Gunn-Moore DA, Gruffydd-Jones TJ and Harbour DA. **Detection of feline coronaviruses by culture and reverse transcriptase-polymerase chain reaction of blood samples from healthy cats and cats with clinical feline infectious peritonitis.** *Vet Microbiol* 1998; 62: 193–205.
148 Kipar A, Baptiste K, Barth A, et al. **Natural FCoV infection: cats with FIP exhibit significantly higher viral loads than healthy infected cats.** *J Feline Med Surg* 2006; 8: 69–72.
149 Li X and Scott FW. **Detection of feline coronaviruses in cell cultures and in fresh and fixed feline tissues using polymerase chain reaction.** *Vet Microbiol* 1994; 42: 65–77.
150 Felten S, Matiasek K, Leutenegger CM, et al. **Diagnostic value of detecting feline coronavirus RNA and spike gene mutations in cerebrospinal fluid to confirm feline infectious peritonitis.** *Viruses* 2021; 13: 186. DOI: 10.3390/v13020186.
151 Sangl L, Felten S, Matiasek K, et al. **Detection of feline coronavirus RNA, spike gene mutations, and feline coronavirus antigen in macrophages in aqueous humor of cats in the diagnosis of feline infectious peritonitis.** *J Vet Diagn Invest* 2020; 32: 527–534.

152 Sangl L, Matiasek K, Felten S, et al. **Detection of feline coronavirus mutations in paraffin-embedded tissues in cats with feline infectious peritonitis and controls.** *J Feline Med Surg* 2019; 21: 133–142.

153 Felten S, Weider K, Doenges S, et al. **Detection of feline coronavirus spike gene mutations as a tool to diagnose feline infectious peritonitis.** *J Feline Med Surg* 2017; 19: 321–335.

154 Jähne S, Felten S, Matiasek K, et al. **Detection of mutated and non-mutated feline coronaviruses in cats without feline infectious peritonitis** [abstract]**.** Proceedings of the 29th annual meeting of the FG 'Internal Medicine and Clinical Laboratory Diagnostics' of the DVG (InnLab), 2021. DOI: 10.1055/s-0040-1722399.

155 Rissi DR. **A retrospective study of the neuropathology and diagnosis of naturally occurring feline infectious peritonitis.** *J Vet Diagn Invest* 2018; 30: 392–399.

156 Tammer R, Evensen O, Lutz H, et al. **Immunohistological demonstration of feline infectious peritonitis virus antigen in paraffin-embedded tissues using feline ascites or murine monoclonal antibodies.** *Vet Immunol Immunopathol* 1995; 49: 177–182.

157 Kipar A, Kremendahl J, Addie DD, et al. **Fatal enteritis associated with coronavirus infection in cats.** *J Comp Pathol* 1998; 119: 1–14.

158 Parodi MC, Cammarata G, Paltrinieri S, et al. **Using direct immunofluorescence to detect coronaviruses in peritoneal and pleural effusions.** *J Small Anim Pract* 1993; 34: 609–613.

159 Litster AL, Pogranichniy R and Lin TL. **Diagnostic utility of a direct immunofluorescence test to detect feline coronavirus antigen in macrophages in effusive feline infectious peritonitis.** *Vet J* 2013; 198: 362–366.

160 Hellemans A, Acar DD, Stroobants VJE, et al. **A comparative study of techniques used for the diagnosis of effusive feline infectious peritonitis.** *Vlaams Diergeneeskd Tijdschr* 2020; 89: 100–110.

161 Howell M, Evans SJM, Cornwall M, et al. **Multiplex fluorescent immunocytochemistry for the diagnosis of feline infectious peritonitis: determining optimal storage conditions.** *Vet Clin Pathol* 2020; 49: 640–645.

162 Ives EJ, Vanhaesebrouck AE and Cian F. **Immunocytochemical demonstration of feline infectious peritonitis virus within cerebrospinal fluid macrophages.** *J Feline Med Surg* 2013; 15: 1149–1153.

163 Gruendl S, Matiasek K, Matiasek L, et al. **Diagnostic utility of cerebrospinal fluid immunocytochemistry for diagnosis of feline infectious peritonitis manifesting in the central nervous system.** *J Feline Med Surg* 2017; 19: 576–585.

164 Addie DD, le Poder S, Burr P, et al. **Utility of feline coronavirus antibody tests.** *J Feline Med Surg* 2015; 17: 152–162.

165 Meli M, Kipar A, Müller C, et al. **High viral loads despite absence of clinical and pathological findings in cats experimentally infected with feline coronavirus (FCoV) type I and in naturally FCoV-infected cats.** *J Feline Med Surg* 2004; 6: 69–81.

166 Negrin A, Lamb CR, Cappello R, et al. **Results of magnetic resonance imaging in 14 cats with meningoencephalitis.** *J Feline Med Surg* 2007; 9: 109–116.

167 Boettcher IC, Steinberg T, Matiasek K, et al. **Use of anti-coronavirus antibody testing of cerebrospinal fluid for diagnosis of feline infectious peritonitis involving the central nervous system in cats.** *J Am Vet Med Assoc* 2007; 230: 199–205.

168 Meli ML, Burr P, Decaro N, et al. **Samples with high virus load cause a trend toward lower signal in feline coronavirus antibody tests.** *J Feline Med Surg* 2013; 15: 295–299.

169 Felten S, Mariasek K, Leutenegger C, et al. **Diagnostic value of detecting feline coronavirus RNA and spike gene mutations in cerebrospinal fluid to confirm feline infectious peritonitis.** *Viruses* 2021; 13: 186. DOI: 10.3390/v13020186.

170 Fish EJ, Diniz PPVP, Juan YC, et al. **Cross-sectional quantitative RT-PCR study of feline coronavirus viremia and replication in peripheral blood of healthy shelter cats in Southern California.** *J Feline Med Surg* 2018; 20: 295–301.

171 Shelly SM, Scarlett-Kranz J and Blue JT. **Protein electrophoresis on effusions from cats as a diagnostic test for feline infectious peritonitis.** *J Am Anim Hosp Assoc* 1988; 24: 495–500.

172 Singh M, Foster DJ, Child G, et al. **Inflammatory cerebrospinal fluid analysis in cats: clinical diagnosis and outcome.** *J Feline Med Surg* 2005; 7: 77–93.

173 Wiggans KT, Vernau W, Lappin MR, et al. **Diagnostic utility of aqueocentesis and aqueous humor analysis in dogs and cats with anterior uveitis.** *Vet Ophthalmol* 2014; 17: 212–220.

174 Linn-Pearl RN, Powell RM, Newman HA, et al. **Validity of aqueocentesis as a component of anterior uveitis investigation in dogs and cats.** *Vet Ophthalmol* 2015; 18: 326–334.

175 Felten S, Matiasek K, Gruendl S, et al. **Utility of an immunocytochemical assay using aqueous humor in the diagnosis of feline infectious peritonitis.** *Vet Ophthalmol* 2018; 21: 27–34.

176 Doenges SJ, Weber K, Dorsch R, et al. **Comparison of real-time reverse transcriptase polymerase chain reaction of peripheral blood mononuclear cells, serum and cell-free body cavity effusion for the diagnosis of feline infectious peritonitis.** *J Feline Med Surg* 2017; 19: 344–350.

177 Pedersen NC, Eckstrand C, Liu H, et al. **Levels of feline infectious peritonitis virus in blood, effusions, and various tissues and the role of lymphopenia in disease outcome following experimental infection.** *Vet Microbiol* 2015; 175: 157–166.

178 Can-Şahna K, Soydal Ataseven V, Pinar D, et al. **The detection of feline coronaviruses in blood samples from cats by mRNA RT-PCR.** *J Feline Med Surg* 2007; 9: 369–372.

179 Hornyák Á, Bálint Á, Farsang A, et al. **Detection of subgenomic mRNA of feline coronavirus by real-time polymerase chain reaction based on primer-probe energy transfer (P-sg-QPCR).** *J Virol Methods* 2012; 181: 155–163.

180 Kennedy MA, Abd-Eldaim M, Zika SE, et al. **Evaluation of antibodies against feline coronavirus 7b protein for diagnosis of feline infectious peritonitis in cats.** *Am J Vet Res* 2008; 69: 1179–1182.

181 Longstaff L, Porter E, Crossley VJ, et al. **Feline coronavirus quantitative reverse transcriptase polymerase chain reaction on effusion samples in cats with and without feline infectious peritonitis.** *J Feline Med Surg* 2017; 19: 240–245.

182 Freiche G, Guidez C, Duarte M, et al. **Sequencing of 3C and spike genes in feline infectious peritonitis: which samples are the most relevant for analysis? A retrospective study of 33 cases from 2008 to 2014: ISCAID-P-5.** Research communications of the 25th ECVIM-CA congress; 2015, Sept 10–12; Lisbon, Portugal. DOI: 10.1111/jvim.13647.

Available online at jfms.com, catvets.com/fip and everycat.org/aafp-fip-guidelines

Article reuse guidelines: sagepub.co.uk/journals-permissions